TREATISE

ON

SOME PRACTICAL POINTS

RELATING TO THE

DISEASES OF THE EYE,

BY THE LATE

JOHN CUNNINGHAM SAUNDERS,

DEMONSTRATOR OF ANATOMY AT SAINT THOMAS'S HOSPITAL,

Founder and Surgeon

OF THE

LONDON INFIRMARY FOR CURING DISEASES OF THE EYE.

TO WHICH IS ADDED,

A SHORT ACCOUNT OF THE AUTHOR'S LIFE,

AND HIS METHOD OF

CURING THE CONGENITAL CATARACT,

BY HIS FRIEND AND COLLEAGUE,

J. R. FARRE, M. D.

THE WHOLE ILLUSTRATED BY COLOURED ENGRAVINGS.

LONDON:

PRINTED FOR LONGMAN, HURST, REES, ORME, AND BROWN, PATERNOSTER-ROW; AND E. COX, ST. THOMAS'S STREET, BOROUGH.

1811.

J. M'Creery, Printer,
Black-Horse-Court, Fleet-Street,
London.

TO

HENRY CLINE, ESQ. F.R.S.

AND

ASTLEY COOPER, ESQ. F.R.S.

UNDER WHOM THE AUTHOR ACTED,

AS

DEMONSTRATOR OF ANATOMY:

TO

THE PRESIDENT,

TREASURER, VICE-PRESIDENTS,

COMMITTEE, AND GOVERNORS,

OF THE

London Infirmary

FOR CURING DISEASES OF THE EYE;

BY

WHOSE MUNIFICENT SUPPORT

THAT

EXCELLENT CHARITY HAS BEEN PERMANENTLY

ESTABLISHED:

THIS WORK

IS

RESPECTFULLY INSCRIBED

BY

THEIR FAITHFUL SERVANT,

THE EDITOR.

Preface.

In offering this tribute to the memory of his friend, the Editor has endeavoured to limit the service to the faithful record of what the Author had written or done.

In the first three Chapters the manuscript was sufficiently complete to admit of publication in the form of distinct essays, in which the Author intended that it should appear; but in Chapter IV. the Editor was obliged to depart from the original plan of the work, and to connect under the stages of inflammation facts which were too valuable to be lost. This advantage, however, arises from it, that the organ of vision is thus subjected to the same general views of disease, and rules of treat-

ment, by which the morbid processes of a similar kind in other organs are controlled.

The arrangement of the cases in Chapter V. is merely intended to point to a practical distinction of some importance. Few cases of the malignant fungi can fall under the observation of an individual; for which reason they are the more worthy of being recorded, and of being illustrated by correct Engravings. It is the only method of communicating to medical men correct notions of diseases which are imperfectly comprehended, and which are apt to be confounded under one generical term.

The Chapter on the congenital cataract has been composed from the notes of the Author, and from direct observation on almost all the cases, public and private, on which he operated.

TABLE OF CONTENTS.

PAGE

THE LIFE OF THE AUTHOR ix

CHAPTER I.

ON INFLAMMATION OF THE CONJUNCTIVA IN INFANTS 1

CHAPTER II.

ON INFLAMMATION OF THE IRIS, AND THE INFLUENCE OF THE EXTRACT OF BELLADONNA TO PREVENT THE CONSEQUENT OBLITERATION OF THE PUPIL 21

CHAPTER III.

ON THE CURE OF THE INVERSION OF THE UPPER EYE-LID BY EXCISION OF THE TARSUS 41

CHAPTER IV.

PAGE

ON SOME OF THE MORE IMPORTANT TERMINATIONS OF OPHTHALMIA:

I. BY EFFUSION OF COAGULABLE LYMPH 59

II. BY SUPPURATION 68

III. BY SLOUGH 70

IV. BY ULCERATION 98

PROTRUSION OF THE IRIS . 102

CHAPTER V.

ILLUSTRATIONS OF SOME OF THE MORE IMPORTANT CHANGES OF STRUCTURE IN THE EYE 115

CHAPTER VI.

ON THE CONGENITAL CATARACT 131

EXPLANATION OF THE PLATES 193

A

SHORT ACCOUNT

OF THE

LIFE OF THE AUTHOR.

JOHN CUNNINGHAM SAUNDERS was the youngest son of John Cunningham and Jane Saunders, of Lovistone, in the county of Devon.

He was born on the 10th of October, 1773, and at the age of eight years was sent with his brother† to a school at Tavistock, where he remained several years,

---

† To his only brother, the Reverend Onesiphorus Sheere Saunders, of Barnstaple, the Editor is indebted for these particulars.

and made considerable progress in classical learning. His education was completed at a seminary at Southmolton, where he remained till the end of the year 1790. He was then placed under the care of Mr. John Hill, surgeon, of Barnstaple. In many instances whilst he was under the tuition of this gentleman, who had a high opinion of his abilities, he manifested much professional acuteness. At the expiration of an apprenticeship of five years, he came to London to complete his medical education, without a single introduction to any one who could direct or assist him in his studies: a circumstance which, in estimating his professional merit, justly tends to exalt his character.

On his arrival in London, among the distinguished schools of surgery for which the Metropolis is justly celebrated, he selected St. Thomas's and Guy's Hospitals, which, for the eminence of the Teachers, and for the extensive field of observation

that they afford, are not surpassed by any similar establishment. In this great school he applied himself to anatomy with the assiduity of one emulous of professional distinction; and so rapid was his progress in the acquirement of it, that at the end of two years the important appointment of Demonstrator of Anatomy at St. Thomas's was conferred on him by the Teachers of Anatomy and Surgery at that Hospital. It is the strongest proof of his merit that Mr. Astley Cooper, on being called to the chair, elected him to the very office which he himself had recently filled. From this period he resided with Mr. Cooper for several years, and as a dresser under him, finished his surgical education.

He continued to discharge the duties of his office with great advantage to the anatomical classes until the spring of 1801, when he resigned it, and went into the country: but in the autumn of the same year he was

induced to return to London, and was re-appointed Demonstrator of Anatomy, which post he filled with increasing reputation to the very winter that terminated his valuable life. His demonstrations, which consisted of a series of practical lessons in anatomy, gave great satisfaction to the classes, and the pupils expressed their acknowledgment of the services he had rendered them, by presenting him on more than one occasion with plate, on which they had handsomely inscribed their sense of his merit, and the grateful expressions of their regard.

After his return to London, the subject of his final settlement occupied much of the attention of himself and his friends, whose warm attachment to him ever increased in proportion to their intimate knowledge of him. He wished to establish himself as a surgeon in London, and with this view took a house in Ely Place. He shortly afterwards (April 7th, 1803,) married Miss

Jane Louisa Colkett, the second daughter of Daniel Colkett, Esq. and had one daughter, who died in her infancy.

In October 1804, he published a proposal of founding a Charitable Institution for the Cure of Diseases of the Eye and Ear. The plan was encouraged by a number of gentlemen, to many of whom he was not even previously known. The Charity was established, and has ever since continued to receive increased proofs of public favour. I now bears the name of the London Infirmary for curing Diseases of the Eye, to which class of diseases it has been found expedient to limit it. Mr. Saunders himself in the following letter noticed its origin, and at the same time announced that he had successfully operated on the congenital cataract, even in infancy:—

"TO THE COMMITTEE.†

"Gentlemen,

"AS you have resolved to submit this Charity in a regular form to the notice of the public, it will not be foreign to the design, if I should revert to the circumstances which attended its origin.—On the 1st of October, 1804, I published a Proposal for instituting a Dispensary for the relief of the poor, afflicted with Diseases of the Eye and the Ear. This Proposal was sanctioned by the testimonials of the Physicians and Surgeons of St. Thomas's and Guy's Hospitals, where I had then been engaged in professional studies ten years, during eight of which I had acted as the Teacher of Practical Anatomy. The plan was immediately encouraged—this Charity was instituted under the name of the London Dispensary

---

† This letter was published by the Committee in their Report of the Progress of the Charity for the year 1808.

FOR CURING DISEASES OF THE EYE AND EAR, and opened for the reception of patients on the 25th March, 1805.

"Subsequently to the date of my Proposal, a similar Institution, honoured with the Royal Patronage, was formed and established in Westminster. Although the Prospectus of the Royal Infirmary was not heard of until many months after the Publication of my Proposal, yet it must be admitted that that Institution first appeared before the Public in a regular and organized form, and this, which is the original, is consequently considered by all who are unacquainted with the facts as the copy. Apprehensive of this impression, I immediately claimed by public advertisements, which were never answered, the priority of my Proposal.

"I should be excused for thus obtruding on your notice if I sought merely the indulgence of honest pride, by maintaining this just claim to respect, but I shall yet

more readily be excused, when you reflect, that if I had abandoned this claim, the Public would continue to regard me as an humble copyist.

"In the return which I have now the honour of delivering to you, the Cured are arranged under the heads of the Diseases with which they were afflicted. In addition to the observations made on the last Report, which are equally applicable to the present, there is one point on which I must beg the indulgence of expatiating; I mean the adaptation of an operation on the cataract to the condition of childhood, by which I have successively cured without a failure fourteen persons born blind, some of them even in infancy, and it has just been performed on an infant only two months old, who is in a state of convalescence. As I reserve for another occasion the communication of the method which I pursue for the cure of very young children, I shall no farther compare it with extraction, than by

observing, that extraction is wholly inapplicable to children, or only fortuitously successful. Those who on all occasions adhere to this operation, and have never turned their thoughts towards the application of means more suitable to this tender age, have been obliged to wait until the patient has acquired sufficient reason to be tractable; otherwise when they have deviated from this conduct, the event has afforded little cause of self-congratulation.

"How great the advantage of an early cure, is a question of no difficult solution. Eyes ORIGINALLY affected with cataracts contract an unsteady and rolling motion, which remains after their removal, and retards, even when it does not ultimately prevent, the full benefit of the operation. A person cured at a late period cannot overcome this awkward habit by the utmost exertion of reason or the efforts of the will. But the actions of the infant are instinctive. Surrounding objects attract attention, and the

eye naturally follows them. The management of the eye is therefore readily acquired, his vision rapidly improves, and he will most probably be susceptible of education about the usual period.

"I am,

"Gentlemen,

"Your obedient Servant,

"J. C. SAUNDERS."

"*Ely Place March* 25, 1808."

During this period others had also profited by that ample field of experience which the Infirmary afforded Mr. Saunders. He instructed Mr. Adams, in the most disinterested manner, in the diseases of the eye, and in the operation for the cataract, which is described at page 165; and thereby enabled him to establish an Infirmary at Exeter, on the model of the London Infirmary. He also admitted Mr. Stevenson to

the practice of the Infirmary, as a pupil, for three months.

In the beginning of 1809, Mr. Saunders announced by advertisement in the medical journals his intention of publishing a Treatise on some practical points relating to the Diseases of the Eye, and particularly on the nature and cure of Cataract in persons born blind. He was so completely occupied with his public and private professional duties, that only a small portion of his time, during the summer months, could be devoted to the labours of an author: yet, when it is considered that not quite five years had elapsed from the establishment of the Infirmary before his valuable life was closed, it must be admitted that he was not inattentive to that service, as he had published during this period a work on the Anatomy and Diseases of the Ear, and an Essay on Inflammation of the Iris, as a specimen of a series which he meant to communicate on the diseases of the eye. In the

course of this year his inquiries on the congenital cataract were nearly concluded, and after the anatomical lectures had closed, he commenced the manuscript of his intended publication. He wrote the Essay on Inflammation of the Conjunctiva in Infants, and on the Cure of the Inversion of the upper Eye-lid by excision of the Tarsus, which together with the Essay on Inflammation of the Iris, form the three first chapters of the following work. But he was not enabled even to correct what he had written. The attacks of the disease which proved fatal to him were now so frequent, the pain of his head was so excruciating, and in his intervals of ease he was so much deprived of that energy of mind which had been natural to him, that although he struggled to redeem his pledge, he was unable to accomplish his intention. The Editor cannot overlook his notes of cases, taken at this time in a tremulous and sometimes illegible hand-writing, without the most painful recollection of his sufferings.

But even in this state he could not be prevailed on to quit the scene of his hitherto active labours for temporary repose in the country.

His disease commenced with the following symptoms: Acute pain of the scalp, investing portions of the occipital and right parietal bones, accompanied with a sensation of icy coldness (unreal) in the affected part, urgent vomiting, pulse sometimes frequent, at others undisturbed. These paroxysms generally passed away in a night, almost always in the space of twenty-four hours, and returned at uncertain intervals. They were excited by a current of cold air chilling the skin, by indigestion, or by anxiety. He was habitually temperate: he disliked wine, and took even malt liquors with caution, for they aggravated the paroxysms of the disease.

He was subsequently affected with an

imperfect amaurosis of the right eye. The eye was carefully examined, but the pupil was found to be of its proper size and figure, and it contracted or dilated in proportion to the quantity of light which fell on the retina. The following circumstances were remarked in the progress of this symptom: luminous bodies, to use his own expression, were shorn of their beams; objects, besides being obscured, were diminished in size, and deranged in position; the accurate distinction of colours was lost, apparently because the action excited by the predominant colour dwelt on the retina. Blood was freely drawn from his neck by cupping, he was confined to a dark room, under a very low regimen, and his bowels were kept open; yet during this period he suffered two severe paroxysms of his disease in quicker succession than usual. They were, in this instance, distinctly accompanied with frequency of pulse, and terminated by sweat. His pulse were na-

turally frequent and very full, like the pulse of a patient under pleuritis, his radial arteries were unusually large.

At the approach of the winter of 1809, the paroxysms of head-ach and vomiting became more frequent. He had sensibly wasted, and was often distressed with dyspepsia and palpitation. In giving his last demonstration, in November, 1809, he felt oppressed by the heat of the room and the numerous class which surrounded him, and was obliged to retire, leaving his demonstration unfinished. His attention was first interrupted by a numbness of his right leg, his expressions were confused, and he continued to repeat the words he had last uttered: although he was conscious of his error, he could not correct it. The voluntary muscles were affected, and he walked with an unsteady pace. From this period he frequently lisped, and had a difficulty in retaining his saliva.

On the 4th of January, 1810, he experienced a similar attack, which chiefly affected the voluntary muscles. He was unable to walk without support. His countenance was pallid and disfigured, and bore, instead of its wonted expression, the character of fatuity. His extremities were chilled. He was relieved by going to bed, and diluting with warm tea. On the following day he was more than usually unsteady in walking. He suffered other attacks of his disease, similar in kind, but varying in their degree, in one of which he fell in the street. He attributed this unsteadiness in moving to a defective sensation, for he did not always distinctly feel the ground. He continued his professional pursuits, and, in the intervals between the attacks, he was capable of walking a considerable distance.

The functions of the alimentary canal became more disordered. Various mild fluids

taken for breakfast, were rejected by vomiting. Nothing was so grateful to his palate as water. His appetite for dinner was irregular, and his stomach would receive only the most simple diet. His bowels were torpid. His heart palpitated more frequently than usual. His skin was pallid: the capillary arteries, far from being loaded, had not matter enough for nutrition; he perceptibly wasted, his mind became unequal, and his spirits low. As soon as the amaurosis of the right eye manifested itself, the evacuant plan was pursued, and stimulants were refrained from to the extent which he could bear. At no subsequent period did his declining strength admit of further reduction. The torpor of his bowels, in the earlier stages of the disease, was relieved by doses of the submuriate of mercury and the compound extract of colocynth, or the sulphate of magnesia: in the latter, by rhubarb, to which was added a portion of the subcarbonate of soda. In the country he was ruddy, and enjoyed health. In the

impure air of a large city, and still more of a dissecting room, to which, during so many winters, he had been exposed, his colour had insensibly faded, and his health had been less vigorous. He was repeatedly, but in vain solicited to reside at a small distance from town.

On the 9th of February, 1810, I was called to him at three in the afternoon, and found him unusually low. He had just dined, and had been induced, from a feeling of languor, to take three glasses of wine, which in him was an excess; but his pulse were not sensibly affected by it. Between five and six o'clock he visited a patient in Ely Place. At nine I again saw him. He calmly conversed with me for nearly an hour on professional subjects, but chiefly on his own case, and especially respecting the palpitation, which so often distressed him. He thought it proceeded from organic disease of the heart. This led me to examine the seat of that viscus. Its pul-

sations were certainly felt lower than usual. His pulse at the wrist were then seventy-four and regular. In a few moments after this examination he complained of a numbness of the little toe of the right foot, and immediately remarked that he had, of late, occasionally felt a pressure about the calf of that leg, even when undressed, as if it were girt with a tight pantaloon. In an instant afterwards he grasped the scalp over the right side of the occiput, the old seat of pain, his face was pale, covered with sweat, and convulsed on the right side. He drew up his right leg and dropped to the right side. He looked at me, and said with a failing articulation, "paralytic fit." He attempted, but could not drink some cold water, which was offered to him. His pulse were now one hundred and forty in a minute. He several times pronounced the name of his wife with an affecting emphasis, and became insensible; a deep apoplectic stertor seized him, and his pulse fell to forty. These

fatal changes were rapid; but at a time of such painful anxiety, it cannot be stated with precision how soon they were accomplished. Ten ounces of blood were taken from his arm with no obvious advantage, therefore the temporal artery was immediately afterwards opened, and sixteen ounces more were rapidly drawn off from it. The stertor ceased, and the pulse rose and became free; but these were the only effects which resulted from the abstraction of blood. He remained without sense or motion, and his pupils were dilated in the utmost degree. His neighbour Dr. Squire, and Mr. Battley had come to his assistance; and shortly after them, Mr. Cline and Mr. Cooper arrived. Mr. Cooper proposed to take more blood from the temporal artery. It was suffered to flow, but it had now almost lost its arterial character, and resembled venous blood. The vital functions were ceasing; respiration every now and then paused, and he expired in the space of

two hours and a half after the apoplectic attack.

It is remarkable that the retina of the right eye, for some time previous to his death, had recovered its sensibility in a degree sufficient even for his professional pursuits.

The following description of the morbid appearances is given by Mr. Astley Cooper, who examined the body three days after death.

" The dura mater adhered firmly to the inner side of the cranium, especially over the right eye; but it was apparently free from disease. The tunica arachnoidea and pia mater were healthy. Although other parts of the body had become changed by putrefaction, the brain possessed an uncommon degree of firmness. On cutting open the lateral ventricles a quantity of coagulated blood was found at the posterior

part of each, and nearly an ounce of bloody serum was discharged. The clot of blood extended from the right ventricle in the direction of its inferior cornu, and that part of the brain, which was in contact with it, had a soft and broken texture. The weight of the clot was at least one ounce. In the pons varolii there was extravasated blood, disposed in streaks.

"The lungs were perfectly healthy, except that the upper part of each had contracted a slight adhesion to the chest. About two ounces of bloody fluid were found in each cavity of the pleura, which was supposed to be the result of putrefaction. The pericardium contained about one ounce of a similar fluid. The heart was large, and its texture so soft that it broke down very readily under the pressure of the fingers; but this was more especially observable on the left side. The valves on both sides of the heart and arteries were sound.

"The stomach was distended with air, and contained a small quantity of undigested matter; its left extremity was discoloured by resting on the spleen. Both small and large intestines wore an healthy aspect, except that the peritoneal coat of the small intestines was in a few places discoloured by putrefaction. The liver appeared of a dark blue colour, but its texture was unchanged. The gall bladder contained a small quantity of bile, and the excretory ducts were not larger than natural. The spleen was of its usual size, and of a deep purple colour. The pancreas was healthy. The kidnies and urinary bladder were altogether free from disease."

Mr. Saunders was of the middle size, well made, and of an engaging mien. His mind was active, but its original bias was not in favour of the medical profession. Warm in his temper, naturally brave, and enthusiastically fond of whatever was truly British, his wish was to have

distinguished himself in the service of his country. But although he was not led by choice to cultivate surgery, from the moment that he engaged in it, he pursued that line of study which most surely led to professional distinction.

He was generous in his private practice, and perfectly unreserved in stating his opinions on the cases submitted to his judgment. In his public practice he truly deserved the title of a benefactor, for he never would accept any remuneration for his services, although a very liberal one was offered to him by the General Committee of the Infirmary. To that honourable body, and to the Governors in general, the Editor feels that every acknowledgment is due for the esteem with which they repaid the labours of the Founder during his life, and for the honours which they conferred upon his remains. A more respectful tribute was never paid to the memory of any medical man. In republishing the proceed-

ings of the General Committee, the Editor on this occasion is anxious to offer in particular a public acknowledgment to Henry Kensington, Esq. the Treasurer of the Infirmary, to Mr. Alderman Ansley, and Richard Heathfield, Esq. Vice Presidents, and to Richard Battley, Esq. Secretary, with whom they originated. To no gentlemen more than to these is the Infirmary indebted for its prosperity, and none had a better opportunity of observing and estimating the services rendered by its Founder. The resolutions were moved at a very full meeting by Mr. Heathfield, and the following particulars, at the request of the Committee, were added by that gentleman in an appendix to the report of the Charity published in 1810.

"THE Committee now address the Governors, under much affliction for the Death of the excellent Founder of this Charity. In MR. SAUNDERS the Members of the Committee have lost a Friend with whom they

were proud to act: the Governors, a scientific and humane dispenser of their Bounty; the Public, a Man in whom great force of genius, integrity, and diligence, were directed with eminent success to a great public object, and whose actual progress was by himself only valued as an earnest of future public good.

"Impressed by considerations inseparable from the melancholy occasion, the Committee, at a Special Meeting on the 14th of February, unanimously agreed to the following Resolutions, viz.

'That the Committee unfeignedly lament the irreparable loss this Charity, and Society at large, have sustained by the Death of J. C. Saunders, Esq. late Surgeon to this Infirmary.

'That this Committee have ever recognised in Mr. Saunders the union of the most singular simplicity of Character with the highest order of talents.

‘ That his Humanity in the treatment of the poor objects of this Charity, has only been equalled by the extraordinary skill he has applied to their relief.

‘ That the adaptation of an operation to the cure of Children born blind with Cataract, afforded the assurance of further extensive benefit to Society, and entitle him to rank as a Benefactor to Mankind.

‘ That the President, Vice-Presidents, Treasurer, and Committee, do attend the Funeral of Mr. Saunders, and that the Governors of this Charity, generally, be invited to join in that mark of respect to his Memory.

‘ That a general Meeting of the Governors be called for Tuesday, the 27th of February, to consider in what manner the sense entertained of the Character and Talents of Mr. Saunders can be further appropriately manifested.

'That a copy of these Resolutions, and an invitation to attend the Funeral, be transmitted to every Governor.'

"And, at the special general Meeting of the Governors which ensued, the Committee had the satisfaction to find the sentiments of the Governors in strict unison with their own, and the following Resolutions were passed with the same unanimity."

'That the work intended to be entitled "A Treatise on some Practical Points relating to the Diseases of the Eye, and particularly on the Cure of Cataract in Persons born Blind;" which was in preparation for publication by Mr. Saunders, be published at the expense of this Institution, for the benefit of his widow.

'That a Subscription to the Work will be an appropriate mark of the respect entertained by the Governors for the me-

mory of the late Mr. Saunders; as every Governor will thus have an opportunity of associating his name with that of Mr. Saunders, and of possessing himself of a Memorial of that estimable Man.

'That in the opinion of this Meeting, the publication of the work will not only be an appropriate manner of conferring a mark of respect upon the memory of Mr. Saunders; but will also promote the objects of the Institution, by extending to the world that knowledge which he so successfully applied to the Poor under its care.

'That the proceeds of the work (free from every deduction) be appropriated to the sole use and benefit of Mrs. Saunders.

'That a book be opened to receive the names of subscribers, and the number

of copies for which they may wish to subscribe.

'That a portrait and bust of Mr. Saunders be obtained and placed in the Committee Room.

'That in the opinion of the Meeting it is expedient that a book be opened to receive subscriptions, towards the erection of a Monument, from such gentlemen as may be desirous of offering that further mark of respect to the memory of Mr. Saunders.'

"In furtherance of these Resolutions, a portrait of Mr. Saunders by Devis, and a bust by Giannelli, are placed in the Committee Room of the Infirmary, and active measures were adopted for the publication of the work at the expense of the Institution; but the Governors having since deemed it more expedient that it should be published in the usual mode, have

carried into effect the principal intention of their Resolutions on the subject in a manner not less beneficial to MRS. SAUNDERS. They have also presented to the work the engraved portrait of the Author.

"The following unfinished draught of an address to the Committee, MR. SAUNDERS put into the hands of his friend and colleague only a few days before his death; observing, at the same time, that he thought it better to rest his claims to the continued patronage of the Governors, simply on the merits of the Medical Report, rather than on any appeal to their feelings. Those sentiments which a characteristic delicacy of feeling induced him to withhold, the Committee deem too interesting to be suppressed, especially as they have now acquired the force of parting words."

'TO THE COMMITTEE.

'Gentlemen,

'Five years have now passed since my proposal for establishing this Infirmary was submitted to your notice, during which I have incessantly and anxiously laboured to redeem the pledge then given to make it a beneficial Institution to Society. My anxiety has been relieved, and my labour consoled in the progress of this Institution, by repeated instances of your respect; and the recollection of them at present only heightens the satisfaction I feel, on finding myself confirmed as the conductor of an establishment supported by liberal and zealous advocates, and possessed of the means of performing an important part in Society, and esteemed by Society for it.

'In prosecuting the object of attracting public attention towards this Institution, I

trust I have kept free from the practice of any disingenuous art. Popularity has not been snatched; but studiously and unremittingly sought: it was expected only as the reward of service; and that share of it which has been gained, is ascribable to the estimation in which the Governors have been pleased to hold this service. I have confided the character of the Institution to the quantum of professional good;—excepting you may be pleased to add, that mindful of being an agent for liberal and philanthropic men, I have always administered with humanity and attention to the feelings of the poor, that relief which their bounty has supplied.'

"They close this brief memorial respecting Mr. Saunders, with the record of the distinguished respect conferred upon his remains.—On Tuesday, the 21st of February, his funeral was attended by a numerous company of Gentlemen, consisting of the Officers and Governors of the Institution,

of Physicians and Surgeons of the highest professional rank, and of Medical Practitioners and Students.

"The Right Reverend John Luxmore, D.D. Lord Bishop of Hereford, who most impressively performed the sacred office of Burial, received at the church the procession, which moved on foot from Mr. Saunders's late residence in Ely Place, to St. Andrew's, Holborn, in the following order:

" THE REVEREND CHARLES PRYCE, M.A.

Curate and Joint Lecturer of St. Andrew's, Holborn, and Joint Lecturer of Christ Church, Middlesex.

THE TREASURER

AND

VICE-PRESIDENTS—Pall-Bearers:

Scarfs, Silk Hat-bands.

MOURNERS:

Crape Hat-bands, Cloaks.

PHYSICIANS AND SURGEONS:

Scarfs, Silk Hat-bands.

COMMITTEE:

Silk Hat-bands, Cloaks.

MEDICAL PRACTITIONERS:

Crape Hat-bands, Cloaks.

GOVERNORS:

Crape Hat-bands.

STUDENTS OF ST. THOMAS'S AND GUY'S HOSPITALS:

Crape Hat-bands, Cloaks.

SECRETARY.

CARRIAGES

OF THE BISHOP OF HEREFORD;
PRESIDENT;
VICE-PRESIDENTS;
GENTLEMEN."

CHAPTER I.

ON INFLAMMATION OF THE CONJUNCTIVA IN INFANTS.

INFANTS, soon after birth, are subject to an inflammation, which, as it affects the tunica conjunctiva in a very peculiar manner, has been most commonly denominated the purulent ophthalmia of infants. If the purulent discharge constituted the essence of this disease, no very good objection could be made to the name, as it applies itself to a fact which is very obvious and striking. But as the appellation arises merely from the strength with which that circumstance strikes the notice of the observer, and does in fact comprehend no more than one symptom, the mind of the inexperienced

practitioner may be too much engaged in it, and may not be sufficiently alive to the stage of the disease which precedes the formation of the purulent discharge. The conjunctiva, which is principally the seat of this inflammation, like all membranes endowed with secretory powers, is prone to undergo a change in consequence of inflammation, by which the properties of it's secreted fluid are altered, as in a certain degree happens in catarrhal inflammation of the membrane of the nostrils, and in a still greater degree to the membrane of the urethra under the irritation of syphilitic virus. In the latter instance the secreted fluid assumes the appearance, if not the properties of pus: so strict a resemblance has the discharge, that the term puriform fluid seems highly eligible. In the inflammation at present under consideration, the discharge resembles pus full as much as the discharge from the urethra in gonorrhœa, and the matter passes through as great a variety of tints, from straw-colour to green, &c.

The inflammation commences by a slight redness on the inside of the eye-lids, particularly about the inner canthi; they are soon covered with a thin gluey matter, which quickly inspissating, fastens them together, and when they are forcibly opened a large gush of tears succeeds. The eye-lids tumify very soon; the viscid discharge increases in quantity and speedily assumes a purulent form, whilst the tumefaction of the palpebræ increases. The conjunctiva now loses its character, its vascularity becomes extreme, and the minute colourless vessels which nourish its own peculiar texture, are so enlarged and turgid with arterial blood, that the larger branches which run beneath it are totally obscured. The surface of the conjunctiva is of a beautiful scarlet, and resembles (to use an anatomical illustration) a finely injected fœtal stomach. The swelling of the palpebræ is so great, that when the child cries, the orbicularis muscle projects the morbid conjunctiva and consequently everts the eye-lids; ejecting

at the same time a considerable quantity of the puriform discharge. As the disease advances, the cornea becomes more or less cloudy, and by the extent of this cloudiness the degree of approaching slough is marked: for the whole of the cornea, if the whole become cloudy, will ultimately slough, and the form of the eye be totally destroyed. I do not mean to say, that in every instance in which opacity of the cornea is apparent, the cornea is about to pass into a sloughy state: on the contrary, opacity is often the mark of a healthy action commencing around the breach of the cornea, for the purpose of restoring the part, and ought to be hailed as a happy omen. I am now speaking of a peculiar duskiness of the cornea, which begins during the progressive state of the inflammation, which is antecedent to any loss of substance, but is indeed a sure sign that such loss is about to take place. When this duskiness comes on, supposing only a portion of the cornea about to slough, the extent of it in the space

of twenty-four hours becomes definite, in the same space of time it becomes elevated and apparently lessened in extent, a groove or fissure forms between it and the rest of the cornea, portions of it are carried off by the discharge and tears, or sometimes it separates altogether in one mass. I have several times washed out with a syringe these little sloughs entire. But although I am as certain of the fact as the most frequent observation can make me, I am equally sure that most commonly when this disease destroys vision, the destruction is accomplished in a more gradual manner, not by a slough of very considerable extent and through the whole depth of the cornea at once, but by a succession of sloughs. In other words, the ulcer left by the casting off of the dead piece of cornea, becomes in turn sloughy, and extends itself by a succession of sloughy surfaces, until the last lamina of the cornea sloughs, or being protruded by the pressure from within, ulcerates, and the aqueous humour escaping, the iris passes through the breach

of the cornea. Already the whole surface of the eye has been in an ill-conditioned inflammation; the ulcer, or rather the surface of the cornea around the protruding iris, is indisposed to heal; so that more and more of the iris protrudes, this in turn ulcerates, and the crystalline and vitreous humours all issue at the orifice.

This is the most violent state of the disease, and is less frequent than a more moderate but still malignant form, in which opacities or small specks are produced by the ulcerative process on some parts of the cornea.

That the inflammation itself immediately destroys the parts by sloughing or ulceration, is a truth of which I am perfectly convinced. I am equally certain too, that the eye is not destroyed by suppuration, as some have supposed. I saw a child, in whom half the cornea was in a perfectly sloughy state, yet the iris was not affected,

as far as was visible through the portion of the cornea still clear, nor was there a particle of matter in the anterior chamber. I foretold that the eye would be lost, and I observed the process; a hemisphere of the cornea completely cast off, and the iris came through the breach.

If we consider the rapidity with which this inflammation extends itself over the whole surface of the eye, and that the destruction of the organ takes place from a sloughing of the cornea, we shall be induced to admit, that it is nearly allied to erysipelatous inflammation. It is true, that this inflammation on the skin produces vesications full of discoloured serum, to which we see no precise resemblance in this case of the eye; for in consequence of the difference in the nature of the surfaces, some variation will take place; but as they coincide in this essential particular, the production of sloughs, I hold myself warranted in considering this ophthalmia of

infants, to be an erysipelatous inflammation of the conjunctiva.

The discharges are only symptoms, varying according to the degrees of the inflammation, and marking its stages.

Setting out on the principle, that the destruction of the eye is accomplished by a mortification of the whole or a portion of the cornea, or that vision is impaired, when the disease is less violent, by ill-conditioned ulceration, I think myself authorized to condemn the indiscriminate use of stimulant injections. A strict antiphlogistic plan is clearly indicated in the commencement of the inflammation. On this account leeches should be applied as near the eyes as possible, and the bleeding from the bites suffered to continue a considerable time. The bleeding will be profuse from the bites of leeches in infants newly born, in consequence of the extreme vascularity of the skin; and a sufficient number should be

applied, so as to produce the effect of general as well as local bleeding, which will be known by the child's skin becoming pale. By this plan the tumefaction of the eye-lids will soon be reduced, which is in itself a sign of subsiding inflammation, the discharge will be more ropy and bland in its appearance, and the vessels within the conjunctiva and sclerotica will begin to appear. In the space of twenty-four hours the danger will be considerably diminished, and the antiphlogistic plan being a little longer continued, the activity of the disease will be subdued:—then by the use of mild astringents, the discharge will gradually cease in the course of a fortnight or three weeks, and the eye will be left free from the most trifling defect.

Some persons, tempted by the sanguine appearance of the conjunctiva, think that drawing blood by means of scarifications of the conjunctiva, is a preferable mode to that of leeches. But it can never be paramount

in its effects to the proper application of leeches in infants, in whom I have stated the bleeding by the latter to act generally on the system, whereas a tea-spoonful or two is the utmost which can be procured by scarification of the conjunctiva. Scarifications, as far as I have seen them employed in the active state of the inflammation, are certainly injurious; they have manifestly aggravated the symptoms; and I conceive it will appear highly improbable, that the infliction of mechanical injury on a part already actively inflamed, can be advantageous—a similar practice does not obtain in surgery on other parts of the body.

But my objections here will be, perhaps, answered by an appeal to experience, and I would willingly enter into a little discussion of the subject. When the activity of the inflammation is gone, the vessels of the conjunctiva that have been engaged in the process, remain preternaturally enlarged. At such time the division of a great num-

ber of them, might cause the whole series to contract, and thus accelerate the diminution of the vascularity, and the adhesive inflammation might only produce a degree of reaction, which would then be immaterial. But the condition of the part is widely different during the progressive state of inflammation. At this stage the wounds of the lancet are only additional stimuli co-operating with the disease, and consequently exasperating the state of the eye. Now those gentlemen to whose experience I may be referred for confutation, have not specified any conditions under which their scarifications have been made, and therefore, I may fairly presume, that they were made after the inflammation was on the wane; and here again, I must observe, that scarifications cannot with propriety be used, if there be any ulceration or sloughing of the cornea produced by the disease; for a division of the vessels would only be an interruption to the restorative process, which may be about to commence.

The disorder of the bowels, which during this attack is considerable, ought to be carefully regarded. The stools are often green, and should be corrected by magnesia and rhubarb. Sometimes the bowels are constipated, and demand the employment of a more active cathartic, Calomel: gr: 1.

Hitherto I have confined my observations on the treatment of the disease, to the progress of the inflammation to its utmost possible height, without producing any disorganization. If the application be made previously to this period, the disease is perfectly manageable, and as far as my experience authorizes me to say, the practitioner may safely give a favourable prognosis. But when the cornea grows dusky (the inflammation still continuing active) the danger is great. It is the unerring harbinger of approaching mortification of the part. Before the obscure part becomes definite, it is impossible to state what the

event may be; however, when it begins to elevate itself, it is not difficult to foresee to what extent the sloughing will take place; and if it be not at once of the whole substance of the cornea, the case is generally under controul, and the destruction of the eye may be prevented. Now, it may be fairly determined, how far the sight will ultimately be affected, by the position and bulk of the sloughy part, with regard to the pupil; bearing in mind, as I shall have occasion hereafter more particularly to explain, that the magnitude of the scar will be very considerably less than that of the slough; nor indeed, if the sloughy part of the cornea should be of the whole depth, ought the eye to be considered necessarily lost; for if it be small, it will only be a case of procidentia iridis, the major part of which cases I shall hereafter prove to be very tractable.

At the time when the slough is about to separate from the living parts, the inflammation has always moderated, and it will

therefore be expedient to resort to astringent applications. Very moderate astringents are the best; for it is well known that these points are not to be gained by force. Half a grain of the sulphate of zinc to an ounce of water, will suppress the discharge more rapidly than a stronger solution. For when these substances are used of a greater strength, they set up an inflammatory process which is prejudicial, and they certainly increase the discharge in the same proportion as they aggravate the inflammation. What I have myself employed, has been a solution of alum, varying from two to six grains to the ounce of distilled water; and I have never had occasion to employ any other astringent. During this period the utmost vigilance is requisite, and the eye ought to be carefully inspected at proper intervals, so that the actual state of the sore may be known. If the practitioner remain in ignorance of this, the blame may be laid to his own supineness, for, I will take on me decidedly to say, that there is no case, in

which, by the assistance of Pellier's elevator, and most commonly without any instrument at all, the eye cannot be sufficiently exposed to see the whole of the cornea. The parts ought to be examined, so that if the ulcer of the cornea, after the separation of the dead part, re-acquires a sloughy surface, proper remedies may be used. Under such circumstances the tonic plan must be adopted. The extractum cinchonæ is a very convenient form. The quantity of a few grains, divided into minute pills, may be given without difficulty in a little pap. I have given the quantity of six grains to a child a month old, every four hours, with the best effect. For the sore, before sloughy, has speedily acquired a healthy bottom, all farther spreading has ceased, and the process of granulation advanced rapidly. It will be difficult for me verbally to characterize the appearance of the sloughy surface. It is cindery—ragged—flocculent; whereas the healing surface is besmeared with lymph, which adheres firmly to the

part on which it is poured out; a halo of lymph deposited in the laminæ of the cornea surrounds the ulcer, and vessels advance towards it from the sclerotica, and may be seen, as it were, running into the lymph. The process of restoration does not seem to be materially affected by the continuation of the discharge, and the ulcer is often healed previously to its total cessation. Indeed the discharge in itself is of trivial import, as it will cease by the use of moderate astringents in the course of a fortnight or three weeks, if there be no ulcer of the cornea; but if there be an ulcer, however favourably this effect of the disease may go on, the discharge will be continued by the irritation, for three or four weeks longer. But only let the ulcer assume the healing appearance, and the eye may be pronounced out of danger.

If the ulcer left by the slough, should extend itself by the ulcerative process only, it must be treated in the manner which I shall

lay down, when I discuss the subject of pustulous ophthalmia. This disease does not, at its first commencement, excite the apprehension of the by-standers, and is generally suffered to advance considerably before any application is made, so that in general (particularly among the lower classes of society) the inflammation is spontaneously decreasing, at the time the surgeon first sees the patient; or otherwise sloughs or sloughy ulcers already exist upon the eye. A person unaccustomed to the observation of diseases of the eye, may, on such occasions, easily be deceived, and think the eye irretrievably gone, when it is really in a state of convalescence: for example, the whole of the cornea may be perfectly opake, so that the iris is eclipsed, and yet this opacity shall be a good symptom, for the healing ulcer is surrounded with a halo of lymph, which will certainly disappear as soon as the part has completely cicatrized.

During the inflammatory process, when-

ever the child cries, a large quantity of puriform fluid issues from between the eye-lids, which at the same time are everted. When the tumefaction is great, the upper eye-lid overlaps the lower, and is always partially everted. Whilst the eye-lids are everted, the conjunctiva remains morbid, and the puriform discharge continues. Frequently, when the activity of the disease is removed, it is necessary to apply compresses on the eye; and the lids being thus retained in their proper place, the conjunctiva will collapse so as to fall within the eye-lids. But the eversion in some cases is so great, that this method alone will be insufficient, and it will be necessary to cut out a very considerable portion of the morbid conjunctiva, after which the eye-lids may easily be returned, and kept by proper bandages in their station; or, what is more manageable, the compress may be crossed by strips of adhesive plaister. In the case which I shall relate by and by, the discharge was as completely re-

tained as possible by the compress and sticking plaister, and yet, during the week in which the eye was kept thus closed and immersed in it, three ulcers of the cornea actually healed, and the discharge ceased, without any application whatsoever to the eyes:—a fact which affords an additional proof that the discharge in itself is not mischievous to the eye. I have also seen children, in whom the discharge had continued for many weeks very copiously, without producing the slightest defect of the cornea; whereas in many cases, in which it had only continued a fortnight previously to their application, all the mischievous effects already recited had taken place. But although the discharge be incapable of doing mischief, yet, on the decline of the inflammation, the conjunctiva is sooner restored from the ill-conditioned state which protracts the discharge, by the use of astringent injections.

The inflammation being abated, the dis-

charge generally ceases in about a week; but the morbid structure of the conjunctiva continues a much longer period: five or six weeks elapse before it becomes smooth and pale, as in the healthy state. Occasionally the conjunctiva remains granular, and requires some attention. The ointment with the nitric oxyd of mercury may be advantageously used to extinguish the last remains of the disease. But this point will be more fully considered in a succeeding part of this treatise.

CHAPTER II.

ON INFLAMMATION OF THE IRIS, AND THE INFLUENCE OF THE EXTRACT OF BELLADONNA, TO PREVENT THE CONSEQUENT OBLITERATION OF THE PUPIL.

Scarcely any disease to which the eye is subject, has a more immediate or rapid tendency to destroy vision, than inflammation of the iris. As soon as this delicate and irritable substance is attacked with inflammation, the brilliancy of its colour fades, it becomes thickened and puckered, the inner margin is turned towards the crystalline lens, and the pupil is exceedingly contracted. The vascularity of the sclerotica is very great, whilst that of the conjunctiva remains much as usual, and it may be easily perceived that the plexus of vessels lies within the latter tunic. The inosculations of those minute vessels are

very numerous, and form a species of zone in the junction of the sclerotica and transparent cornea. The vessels disappear at this part as they penetrate the sclerotica, in order to pass to the inflamed iris, and are not continued over the transparent cornea, as in a case of simple ophthalmia. The irritation, on exposure to light, is distressing, and the patient is much incommoded by any pressure on the globe of the eye, or by its rapid and sudden motions. Considerable uneasiness is felt over the eyebrow, and acute lancinating pains shoot through the orbit towards the brain. Occasionally, when the inflammation is violent and extends to the other tunics, the eye is totally destroyed by suppuration. But it rarely advances to this extreme. The inflammation generally terminates in the adhesive stage. Lymph is then deposited on the anterior surface of the iris, and between the iris and capsule of the crystalline lens; and often in so large a quantity, as to extend through the pupil and to drop

pendulous to the bottom of the anterior chamber. If this process be not interrupted, the pupil is entirely obliterated; or the iris adheres to the capsule of the crystalline lens, leaving only a very minute aperture, which is most commonly occupied by an opake portion of the capsule, or of organized lymph, and the patient is totally blind. Red vessels appear on the anterior portion of the iris, running in a thin adventitious membrane, which the adhesive process causes to be formed. This is the usual catastrophe of an inflamed iris, abandoned to the natural process. It is some consolation to think that this state is not absolutely irremediable. The patient has a chance of relief by submitting to an operation for cutting an aperture in the iris, and removing the opake capsule and crystalline lens. But it is not my intention to handle this point. My inquiry is entirely directed to the most eligible mode of treating this state of the eye, and preventing the obliteration of the pupil. I am confident I shall be

able to shew that inflammation of the iris is manageable, and that, if it should have advanced to the deposition of lymph, and even in a certain degree to the organization of that lymph, the obliteration of the pupil may still be prevented, and a very good degree of vision preserved.

As to the first part of this process, whilst the action of the vessels of the iris is simply increased, and no lymph is deposited, we are to be guided by the symptoms above-mentioned, viz. the aspect of the iris, the appearance of the vessels on the sclerotica, and the contraction of the pupil, and should immediately have recourse to the most vigorous means of relief. The application of leeches, mild laxatives, and a simple regimen, the ordinary practice in a common ophthalmia, will be inadequate. In a healthy person labouring only under this local disease, blood-letting in a degree sufficient to reduce the pulse very considerably, most active cathartics, and depriva-

tion of solid food, will be barely sufficient to stop its progress. For no great degree of action is requisite to complete the mischief; a small quantity of lymph will suffice to unite the iris to the capsule of the lens. In an adult, where there is no contra-indication, sixteen to thirty-two ounces of blood may therefore be taken in the course of twenty-four hours; but the quantity must be regulated by the judgment of the practitioner. I only mean to inculcate the necessity of taking a sufficiency to reduce the pulse and arrest the symptoms, and that if the symptoms should recur as the pulse rises, the bleeding should be repeated. I have generally taken away blood by opening the temporal artery. Some may be inclined to think that the division of this artery will diminish the quantity of blood in the inflamed parts. But is it not immaterial whence the blood is taken? Is not the benefit which the division of the temporal artery produces simply in proportion to the necessity of reducing the force of the

circulation, and therefore in the ratio of the quantity of blood abstracted? Can it be conceived that the division of the artery will be effectual in lessening the quantity of blood, when we consider how many small vessels concur to supply the globe of the eye and parts situated in the orbit? The more minute any set of vessels are, the more frequent their inosculations; and it may fairly be presumed, that if all the vessels were divided which distribute branches to the orbit, and from their situation are divisible, whilst the vis a tergo remained the same, the inflammation would not be reduced. Our chief object is, therefore, to impair the force of the heart, and nothing will more completely accomplish this intention, than the abstraction of blood. Whatever other means medicine furnishes, may be employed with the same view. It may therefore be right, after the exhibition of cathartics, to employ the tartarized antimony in moderate doses, in order to enfeeble the pulse. If vomiting be excited

by it, I see no cause of regret, as the straining of the eye in the act of vomiting is more than compensated by the weakness of the pulse which the state of nausea produces.

General blood-letting, with the means here recommended, will often reduce the inflammation; but, after a degree of general bleeding, which the practitioner may be unwilling to exceed, or in a constitution where it may be injurious, the application of leeches is a powerful auxiliary. The best method is to apply them as close as possible to the eye, and to repeat their application at short intervals, so as to keep up a perpetual oozing of blood from the neighbouring vessels, and to prevent the complete turgescence of those which are inflamed. If the inflammation should stop at this stage, the cure will be completed by covering the eye with a weak solution of cerussa acetata, and keeping the patient in a darkened room until the iris is restored to

the proper exercise of its functions. But this is not the ordinary termination of inflammation of the iris; it generally passes on to the adhesive stage. Lymph is deposited between the iris and capsule, and becoming organized, unites them. Whether the capsule of the lens partakes of the original inflammation, is matter of doubt. I have found, in the examination of adhesions between the iris and capsule of the lens, that the vessels have been derived principally from the iris; and it is a well known fact respecting the formation of adhesions, that, when two surfaces are thus joined, most of the vessels proceed from that which is most active, *i. e.* the surface most inflamed.

It has already been stated, that inflammation of the iris is attended with a remarkable contraction of the pupil; and the lymph, which at first simply agglutinates the iris and capsule, ultimately consolidates them, and an immoveable opake substance

is interposed between the light and the immediate organ of vision, the retina. The pupil is seldom *completely* obliterated. An aperture, about the size of a pin-hole, is left in the iris; but this is rarely beneficial to the patient, as it is occupied by some opake matter. Although, in the natural and healthy state of the eye, all the various motions of the iris result from impressions on the retina, to which, as a regulator of the quantity of light, it acts in perfect subserviency; yet the contraction of the pupil, which happens during the inflammation of the iris, must not be regarded as a sympathetic action: on the contrary, its cause is to be sought in the irritation of its muscular fibres, which the inflammation occasions; for, however the stimulus of light may be withdrawn from the retina, the contracted pupil remains stationary. The indication, in the management of this state of deposited lymph, is, to effect, as much as possible, the dilatation of the pupil, that when the iris shall be fixed to the capsule

of the lens, as it certainly will be by the adhesive inflammation, there shall remain a sufficient aperture to transmit light to the bottom of the eye. The larger this aperture the better, as the pupil is generally rendered to a certain degree opake by the lymph which has been deposited on the capsule of the lens. Happily, we are furnished, in the extract of belladonna, with a perfect specific for this purpose. It is already well known, that the application of this substance to the surface of the conjunctiva, excites so strong a contraction in the radiated fibres of the iris, that the pupil is remarkably enlarged, and the whole of the crystalline lens becomes apparent.

We observe certain natural actions in the iris. We see the pupil diminish by the contraction of its circular fibres; and enlarge by the contraction of the radiated, according as the retina sustains a greater or less degree of light. These are its sympathetic actions with the retina. Again, we

perceive that, if one eye be shaded whilst the other is exposed to a strong light, both pupils will be contracted, but not in the same degree as each pupil would be, if both eyes were exposed to the same light. Therefore the iris acts in association with its fellow, and the association is stronger, as the sympathy between the iris and its retina is weakened. In a case of gutta serena in one eye, the most complete I have ever observed, and which had existed thirty years, the iris annexed to the insensible retina varied precisely as the iris of the sound eye was affected by the changes of light to which it was exposed.

The stimulus of the belladonna destroys, for a time, both the sympathetic and associated motions of the iris. Under its influence, the radiated fibres are permanently contracted, and the iris does not change its state in obedience to any impulse of light on the retina; much less from association with the other iris. It has, there-

fore, a specific influence in exciting a strong contraction of the radiated fibres; and this influence is so great, that in the utmost dilatation of the pupil, which has attended the most perfect insensibility of the retina, I have invariably caused a still greater dilatation by the application of belladonna. Indeed, in a case of trembling cataract, where the lens undulated in the vitreous humour, and the iris vibrated with the motions of the eye, as a rag floating in a stream would be agitated by the impulse of the current; when, from inspection of the iris, one would have conceived it to be perfectly inert, I excited a visible action by the belladonna.

Now this substance, if properly applied to the eye during the adhesive process of inflammation, will cause the inner margin of the iris to expand and recede from the axis of the pupil, and will thus overcome the restraint arising from the agglutination of lymph, by elongating the organized bands

which connect the iris and capsule, if they have not been of long duration. Thus the adhesions are drawn out to a degree of tenuity, and consequently transparency, and a considerable quantity of light is admitted. If the effect of the inflammation has been slight, the adhesions will be trivial, and the pupil only slightly irregular. The iris will retain a certain power of action, and vision will be very little injured. In general the pupil is misshapen, and the iris perfectly fixed; but if the aperture be of sufficient size, and the capsule not rendered too opake, the patient will enjoy a very useful degree of sight. The reader will observe, that in this communication I have been speaking of inflammation of the iris, as of a disease which I have often seen uncombined with any superficial ophthalmia. It must, however, be granted, that generally an inflammation of the conjunctiva, in a greater or less degree, is associated with it; but unless there be deep ulcerations, or sloughing of the cornea, the treatment of

the case will not materially vary. But this state of the iris sometimes arises from syphilis. Then the general plan of treatment here proposed must be changed for the specific remedy, and mercury must be vigorously exhibited, if it be proposed to obviate the effect of inflammation, which is the same whether the inflammation be general or specific. In either case the use of the belladonna is equally advantageous.

CASE I.

James Bradshaw, a young man, robust, and of a florid complexion, applied at the Dispensary, March 27th, 1805, being afflicted with a violent ophthalmia that made him blind in the right eye. There were evident marks of inflammation of the iris, but this was complicated with a considerable superficial ophthalmia and diffusion of lymph in the transparent cornea. He was treated much according to the plan incul-

cated in this Essay for the space of a fortnight, but without any success. Disappointed in the employment of means, which I thought must have proved effectual in suppressing pure inflammation, I was induced to investigate the case with the most particular attention. I found on examination a painful and contracted state of the elbow, but no enlargement of the bones or thickening of the ligaments. This symptom, in conjunction with the state of the eye, determined me to treat the case as syphilis. In the space of ten days the inflammation had decreased, the transparent cornea was clear, and the state of the iris perceptible. The pupil was very minute, and evidently opake, and the patient, notwithstanding the restoration of the cornea to its original transparency, could barely perceive the largest objects. The mercury was continued, and the inflammation had subsided, still the sight improved very slowly, in consequence of the contraction of the pupil. I now applied the extract

of belladonna three times in the day. In the course of twenty-four hours the pupil was drawn into a most irregular figure. Two bands, attached to the inner margin of the iris, and joining each other like the letter T, cut the pupil as it were into three. These bands were gradually elongated, and became extremely minute. The belladonna was continued to the latter end of June, when the pupil had nearly recovered its circular form, and his vision being extremely good, scarcely, if at all, inferior to that of the other eye, he ceased to attend any longer at the Dispensary.

CASE II.

J. Richardson applied at the Dispensary, Nov. 29th, 1805, on account of acute inflammation of the iris, the pupil being much contracted and opake from the deposition of lymph. This eye was nearly blind on his admission. He lost a pound of

blood by opening the temporal artery, and was treated in other respects on the plan previously laid down. Dec. 6th, the inflammation had subsided, but the pupil still remained contracted and opake, and vision very imperfect. The extract of belladonna was now applied three times a day; and at the same time, proper means were taken to expedite the absorption of the lymph. Jan. 20th, he left the Dispensary, being restored to perfect vision. The iris enjoyed a certain degree of action, but the pupil could not dilate to an equal degree with that of the other eye, the iris being restrained by its attachment to the capsule of the lens.

CASE III.

Jan. 23d, 1806, Mary Skinner, a woman of a plethoric habit, applied at the Dispensary, labouring under acute inflammation of the eye. The pupil was contracted,

and rendered opake by a deposition of lymph. She was blind on her admission. The temporal artery was divided, and she was otherwise treated on an active antiphlogistic plan. On the 31st, the inflammation had subsided, the pupil was a little clearer, and she could distinguish large objects. Feb. 5th, the pupil was still contracted as at first. I now applied the extract of belladonna: in the course of two days the pupil was considerably enlarged and oval; and by the exhibition of proper remedies, the lymph occupying the aperture was nearly absorbed. The iris, however, remains fixed by adhesions, and the pupil does not vary. Her sight is very good.

CASE IV.

Ann Row, Feb. 14th, 1806, applied at the Dispensary, after an ophthalmia of the left eye, which had spontaneously subsided. She remained blind. On examination of her eye, the pupil was very small, oval,

and occupied by lymph. No symptom of inflammation was now present. She took calom. gr. ij. every night, and every other morning a brisk cathartic. The extract of belladonna was applied three times a day. The pupil enlarged under its application to a very proper size, but was oval, considerably opake, and perfectly fixed by adhesion of the iris to the capsule. Enough was clear to admit of her seeing objects of moderate size. She could distinguish well enough to tell the time by a watch within a second or two. The defect arose, not from the contraction of the pupil (that was sufficiently opened by the belladonna), but from the remaining opacity of the capsule. She left the Dispensary, April 10th, as I could not render any more service by the continuance of this plan.

CASE V.

April 23d, 1806, Margaret Onbird was recommended to my care by Mr. R. Pugh,

jun. of Gracechurch-street, being blind in one eye. In this instance an ophthalmia, which had not been very severe, had terminated spontaneously some time before her application. The pupil was contracted, irregular, and opake. She was treated precisely as the case recited above. In the course of a fortnight the pupil was much enlarged, but nothing could be more irregular, in consequence of the adhesions being elongated by the retraction of the iris. She has continued the plan to the present time. The pupil is less irregular, having assumed an oval form, and is tolerably clear. She can now read a moderate print with this eye; but, on her application, could not perceive a single letter of the largest dimensions. The pupil, although large enough, is perfectly fixed, as in the former instance.

June 16, 1806.

CHAPTER III.

ON THE CURE OF THE INVERSION OF THE UPPER EYE-LID, BY EXCISION OF THE TARSUS.

The exquisite perfection of the human body, in all ages a theme of the philosopher's admiration, is confirmed by the labours of the pathologist. Led by his investigations to observe the excellence of the original structure of the organs, and the changes which they suffer from accident and disease, he still finds, even under the condition of great mutilation, that their functions, although impaired, are performed. Every integral part of our frame is shewn by the anatomist to consist of a series of mi-

nuter parts, of which some are indispensable, others are superadded, in order that its operations may be accomplished in the best of all possible modes.

Surgery is very rarely able to reinstate the parts which are the subjects of its operations in the full possession of their original powers. All which can be accomplished by it, is more commonly only an exchange of a greater defect for a less. The surgeon ought not to overrate his art; he must yield to the condition of nature. To distinguish, in the composition of the organs, between the parts which are principal, and those which are accessory, is his chief object, as the latter may be often sacrificed for the benefit of the system, when their structure is so changed, that the operations of that system, to which they belong, cannot proceed. The excision of the tarsus and the skin, containing the roots of the cilia, is an operation which, by reflecting on their particular office, was suggested to my

mind for curing the inversion of the eye-lids, and I shall establish its expediency, safety, and certainty, not by hypothetical reasoning, but by the decisions of experience.

Among the parts which are subservient to the eye, the eye-lids hold a conspicuous station. They are so nicely adjusted to the surface on which they move, that they are enabled most perfectly to co-operate. The eye-lids may be considered as curtains advanced before the eye, that may be opened and shut at will. If no other object were sought than the occasional closing of the eye, for the temporary suspension of the sense, a simple elongation of the skin endowed with muscles would, perhaps, have been sufficient; but nature, consummate in design, and omnipotent in the execution of it, has foreseen all things which can concur for the safety and protection of the organ, and the perfection of the sense. For these reasons the cilia are given: they

are placed in the margin of the eye-lid in such a direction, that they are a safeguard to the eye, by repelling particles that would otherwise strike on its surface; and they increase, under certain circumstances, the distinctness of vision, by intercepting the perpendicular rays of light. If we are led to an examination of the final cause for which the tarsus enters into the composition of the palpebræ, we may conclude, from the event of its extirpation, that it is more in relation to the cilia than the muscles. From its firmness and elasticity, it is a support to the other parts of the palpebræ, and a protection to the eye, and its concavity being perfectly adapted to the convexity of the globe, the muscles effect their motions with greater celerity and precision; yet its principal use is to sustain the roots of the cilia on the exterior surface of its ciliary margin, which maintains a given position, and thus enables the hairs to lie in that direction which was intended by nature. It is evident, that the cilia

could not sustain themselves on the margin of a flexible substance, acted on by strong muscular fibres; the contraction of the orbicularis would perpetually invert them. The existence of cilia, therefore, necessarily calls for the existence of the tarsus.

These are the only necessary observations to be made relatively to the structure of the eye-lids, in regard to the disease which is the subject of this essay. If any one finds it expedient to revive his ideas of their structure, these points are minutely treated in systems of anatomy. I write only for surgeons, and I conclude that they are acquainted with anatomy, as I cannot perceive with what propriety any one can undertake operations on the human body without this necessary knowledge.

The superior palpebra when inverted in the slightest degree, is the cause of a most vexatious irritation on the eye; but when a large portion is inverted, the case becomes

most distressing from the violent ophthalmia which is produced. No disease of the eye is more intolerable. The friction of the cilia on the eye is never intermitted, and the patient's health and strength fail through the never-ceasing irritation. The cornea is ulcerated, and becomes opake in consequence of the inflammation, and the sight is ultimately destroyed. Nor is this a termination of the unfortunate patient's misery; except, as occasionally happens, the cornea thickens and indurates in an extraordinary degree, assuming a shining white appearance, like a macerated ligament; and then the patient's repose is found in the insensibility of this new-formed substance.

The appearance of the disease in its inveterate form is truly disagreeable. The discharge, the copious flow of tears, the excoriation of the cheek, the opacity of the cornea, the villous, granular, or fungous conjunctiva, render it a disgusting spectacle.

The patient carries his head obliquely, and, in the most awkward manner, attempts to bring the pupil opposite to the objects which he wants to see, without exciting the common actions which take place for such purposes. And this may easily be explained, without any subtilty of exposition. In the natural state of the eye, not only are the eye-lids in form accurately adjusted to the eye, but, for wise purposes, certain motions are associated. Thus the Levator Oculi and the Levator Palpebræ Superioris always act together, or the eye would only be elevated to be lodged under the eye-lid, and the pupil would be covered. But when the patient attempts to look up, there is an accession of pain; for at each endeavour in the Levator Palpebræ to elevate the eye-lid, as this motion cannot be accomplished, the only result is, that the ciliary margin is drawn towards the globe forcibly, and the cilia are more closely applied to the cornea, which, at

the same time, is passing up in a direction contrary to the points of the cilia, and the friction is more intense. In all cases, the patient practises awkward motions to see objects, without turning the eyes in a direction which increases the friction; but he, who has the upper eye-lid inverted, in order to evade any turning up of the eye, distorts the head so as to have the appearance of a wry neck.

This picture which I have drawn, although melancholy, is not overcharged. Considering that I am addressing men acquainted with human misery, it may be deemed superfluous; but I am anxious that this truth should be impressed on the reader's mind: that the excision of the tarsus and roots of the cilia, however severe and formidable in apprehension, is instituted for the cure of a most excruciating disease, and that the occasion demanding it is imperious.

It will not, perhaps, be of very material importance here to investigate the causes which lead to the inversion of the upper eye-lid. Most probably in all instances, excepting burns or wounds, inflammation is the primary cause. This disease is rarely met with among the opulent; for these, although equally liable to inflammation as the poor, are not equally exposed to the dreadful results of it, having it in their power to obtain proper medical assistance; at least, they are not compelled to labour, and are therefore capable of avoiding the aggravation of the disease from exertion, which must be admitted to be at least as great an evil as the former is a benefit. By frequent ophthalmia, attended with ulceration of the conjunctiva, and, lastly, of the tarsus itself, such a vicious bending of it takes place, that every attempt at re-establishing its original position must be fruitless. Although, by detaching it from the external and inner canthi, and by keeping it everted for a considerable time, until

the incisions be healed, the ciliary margin may, for a time, be clear of the eye; yet this flattering appearance, increased by the temporary relief of the patient, together with the returning transparency of the cornea, the friction being taken off, is but of short duration. The altered state of the tarsus preventing its accommodation to the surface of the globe, is not corrected; and so great is the tendency of this diseased substance to incurvate, that the inversion of the eye-lid very soon is again confirmed. What, then, shall we do? Shall we persevere in unsuccessful attempts to cure the patient, by re-establishing the parts in their original and perfect state? When the tarsus is completely changed, this object is impracticable; and it is our duty, as it is decidedly in our power, to emancipate the patient from his misery, by its excision —an operation, which, although it leaves the person in a state less perfect than we could wish, leaves him in the most perfect state that his condition admits of.

The operation proposed by Dr. Crampton, is highly successful, and, as I am inclined to think, unexceptionable in the earlier periods of the disease, before an unconquerable inclination of the tarsus towards the globe is produced; but in this ultimate and inveterate state of the disease, in which the contraction is often consequent on the cicatrization of the tarsus itself, it is altogether inexpedient. It is unadvisable both on the part of the patient and the surgeon; the latter is exposed to censure by his unsuccessful operation, the former is deterred by the pain which he has undergone, and, in despair, abandons himself to his fate. Now, the extirpation of the tarsus, which I have executed with the most happy results, is much more easily performed, and, subsequently to the performance, is followed with no pain or uneasiness to the patient. The certainty of its relieving the patient, is what I more value

than the credit, if there be any, of having suggested it.

The opinion expressed by Dr. Crampton, respecting the insertion of the levator palpebræ, contrary to the explanation of former anatomists, I find to be perfectly correct: that it is inserted into the integuments and conjunctiva. This insertion of the levator led me to suppose, that, if the tarsus were removed without the destruction of the muscular fibres, these preserving almost entirely their former attachments, no particular shortening of the eyelid would arise from it. Now this actually turns out to be the case; and the deformity is not considerable. But, in judging of the deformity, we must not institute the comparison with the perfect state, but with that of the disease; and then we shall observe, that the appearance of the person is manifestly improved, whilst he is at the same time relieved from a most miserable condition, and is very often restored to a

perfect state of vision, except the thickening of the cornea shall have too far advanced.

A piece of thin horn, or a plate of silver, having a curvature corresponding with that of the eye-lid, is to be introduced, and its concavity turned towards the globe, within the eye-lid, which is to be stretched upon it. An incision is to be made through the integuments and orbicularis palpebrarum immediately behind the roots of the cilia to the tarsus, and should extend from the punctum lachrymale to the external angle. The exterior surface of the tarsus is then to be dissected until the orbital margin is exposed, when the conjunctiva is to be cut through directly by the side of the tarsus, which must now be disengaged at each extremity—the only caution necessary being to leave the punctum lachrymale uninjured. Nothing can be more simple than this piece of dissection; and if any embarrassment arises, it is

from the hemorrhage of the ciliary artery, which must necessarily be divided, and this hemorrhage renders it somewhat difficult to observe the punctum, when one wishes to divide the tarsus by the side of it. If the operation itself be simple, the subsequent treatment is still more simple than the operation. In a word, no dressing is necessary, and it is only advisable to cover the eye to conceal a disagreeable object from the patient's friends. In a few days an union will have commenced between the section of the integuments and conjunctiva, and the elevation of the skin will go on like that of the original eye-lid, less complete indeed, but sufficiently so to leave the pupil clear during a moderate elevation of the eye. In all the patients on whom I have operated, a fungus of considerable size has sprouted from the centre of the section. This must of course be managed by caustic or the knife; and the latter is to be preferred, because it excites no subsequent irritation.

A partial inversion of the cilia is very frequently produced by a small cicatrix on the interior surface of the tarsus, by the contraction of which a portion only of the tarsus, together with certain of the hairs annexed to it, is turned against the cornea. This partial inversion is oftener vexatious than dangerous, as the patient, when informed of the cause of irritation, relieves himself by extracting the offending hairs. Provided the roughness of the cicatrix be not sufficient to cause any hurtful friction, the radical cure is within the patient's power, and may be obtained on very easy terms. Let a similar substance be introduced between the ball of the eye and the tarsus as for the excision of the tarsus, and the eye-lid being firmly supported and stretched, a piece of skin, containing the roots of the inverted cilia, must be dissected out.

The inferior palpebra, as it is similarly formed, is subject to the same causes of in-

version as the superior, viz. contractions and changes of the figure and structure of the tarsus from inflammation and ulceration. No cases of inversion from these causes have occurred to me; but I have had several instances of it in consequence of encysted tumors. When these form between the conjunctiva and tarsus, their globular form affects the eye-lid, before they acquire much bulk. They are so situated, that, in proportion as they increase, they carry the orbital edge of the tarsus outwards, and, in the same proportion, the ciliary edge will be made to approach the globe. The irritation which they produce excites the contraction of the orbicularis, and those fibres that lie on the margin of the eye-lid cause it to roll on the little tumor, and the tarsus and cilia are lodged between a fold of the skin and the eye-ball. When the eye-lid is once inverted, every contraction of the orbicularis confirms the disease, which can never be spontaneously relieved by any natural effort of the parts.

An inversion of the inferior palpebra is not unfrequently produced by inflammation of the conjunctiva, and is very easily obviated by keeping the eye-lid depressed by strips of adhesive plaister. Every one must have noticed in ophthalmia the enlargement of the portion of conjunctiva that connects the eye-lids and the globe. It very often lies as a distinct membranous fold between them, and in cases of very severe ophthalmia occasionally protrudes. In cases wherein the irritability of the patient occasions a violent nictitation, this species of inversion occurs; for the tumefaction of the conjunctiva causes a kind of roller to be formed just against the orbital edge of the tarsus, by which it is determined outwards; and over this roller, by the strong contraction of the orbicularis, the eye-lid is turned and lodged between the projecting conjunctiva and the eye. Just as this inversion has commenced, the simple restoration of the eye-lid to its proper position, and keeping it there, will be suf-

ficient. If the proper means for stopping the ophthalmia be at the same time employed, the inflammation subsiding, the conjunctiva will collapse and contract, and the cause of the inversion will be withdrawn. But if this be neglected, the roll of conjunctiva, exposed to pressure and friction, will thicken and indurate to a very great degree. I recommend the excision of this part of the conjunctiva which is thickened, and is the cause of the inversion; after which operation it will be requisite to apply a compress, that will carry the orbital edge of the tarsus inwards. This compress will resist for a time the contraction of the orbicularis, and when the cicatrization at the orbital margin is complete, the eye-lid will maintain its proper situation.

CHAPTER IV.†

ON SOME OF THE MORE IMPORTANT TERMINATIONS OF OPHTHALMIA.

I.—BY EFFUSION OF COAGULABLE LYMPH.

THE cornea is nourished by colourless vessels, that the design of its formation may be accomplished. Notwithstanding the peculiarities of its structure, it is susceptible of very high degrees of inflammation, under which coagulable lymph is ef-

† In this Chapter, the passages which are included between asterisks, and the cases, are inserted from the Author's Notes.

fused between its lamellæ, and especially between its anterior lamella, and the portion of the conjunctiva which is intimately united to it. If the inflammation pauses at this stage, although the opacity be total, the lymph, which has been deposited, is not organized, the interstitial texture of the cornea is only loaded with it, and on the decline of that action of the capillary arteries which occasioned its effusion, the lymph will be gradually removed by the absorbents. But if the inflammatory action prevails, the deposition of lymph is increased, and the process of its organization may be distinctly observed. Red vessels from the sclerotica and conjunctiva advance towards the bed of lymph, and shoot into it in straight lines. The thicker layer of lymph first receives them, and beyond this organized mass is diffused a halo or fainter circle of lymph. By active treatment the effusion is arrested, the red vessels contract and disappear, the lymph

which had been deposited is absorbed, and the cornea recovers its transparency.

The adhesive inflammation sometimes pervades the anterior chamber, so that lymph is not only deposited between the lamellæ of the cornea, but also between the cornea and iris. The quantity effused into the chamber varies. It may occupy only a line in the form of a crescent, immediately above the junction of the cornea and sclerotica; it may accumulate up to the very margin of the pupil, or even rise in irregular masses above the pupil. The effusion of lymph is often limited to the anterior chamber; but the inflammation may extend to the posterior chamber also, and then the capsule of the crystalline lens will become opake, the pupil will adhere to it, or even be filled with coagulable lymph, remaining fixed, irregular in its figure, or very much contracted.

At uncertain periods after the deposition

of lymph within the anterior chamber; the process of its organization commences. Red vessels shoot more readily from the iris into the lymph which has been deposited on that membrane, than from the junction of the cornea and sclerotica into the lymph which has been effused from their internal surfaces; yet they may be distinctly observed to proceed from this source also.

The eye is in considerable danger during this stage of inflammation; and it is of the utmost importance to arrest the effusion of lymph, and thus to prevent the growth of new vessels—a process often fatal to the natural structure. To particularize the treatment would be only to repeat what has been already recommended in the chapter on inflammation of the iris.

The above remarks apply to the adhesive stage of simple inflammation. The following are to be considered as additional ob-

servations on the same stage of syphilitic inflammation of the iris.

* The diseased masses of lymph are originally deposited on the coloured superficies of the iris, and secondarily the posterior surface may be inflamed; but whenever the pupil is obliterated from this cause, it is in consequence of the long continued superficial disease. The pupil is generally large at the first attack of the disease. In the case of Mr. S. coagulable lymph was effused up to the edge of the pupil, the cornea was very obscure, a circular mass of lymph was deposited in the pupillary edge of the iris, and at last assumed a scarlet appearance in consequence of the lymph becoming vascular; ultimately it was absorbed, and only a slight adhesion at one point was discernible. In a case of Mr. Haslam's recommendation, the masses of lymph were pendulous from the edge of the pupil into the anterior chamber.*

* The diagnosis between syphilitic and simple inflammation of the iris may be formed from the following appearances:—In the syphilitic, the iris is much more thickened and puckered, the texture appears more changed, the irritation on exposure to light is less, the pain is most intense at night, red vessels are seen in the substance of the iris—a circumstance not often observed in the early stage of simple inflammation of the iris, in which patients, from the severity of the pain, are sooner induced to apply for relief—the pupil is not so much contracted as in the simple inflammation; and although the general appearance of disease be greater, the pain is actually less, the blindness is often total:*—to which, perhaps, may be added, that the lymph is deposited, as it were, in drops, and assumes a tubercular appearance.—*See plate* I. *fig.* 1, 2.

CASE I.

* Mr. R. applied, totally blind; the pupil was oblong, irregular, and large; the iris puckered, thickened, and full of vessels; the eye-ball enlarged; the vascularity of the sclerotica was not great. The disease had been for a long time treated as simple inflammation. He was completely cured in a fortnight by taking eight grains of calomel daily.*

CASE II.

* Dec. 1st. Mr. T. applied, totally blind from an ophthalmia of a week's duration. The eye-ball was enlarged; the iris very much diseased; the pupil dusky, oval, but in the highest degree irregular. From its appearance I pronounced it to be syphilitic, and gave him two grains of calomel with half a grain of opium every five hours. In

two days the tumefaction was less, in a week he began to see, and in a fortnight the pupil became nearly regular, large, and clear.

Dec. 14. He could read small print. Six grains of calomel were continued daily.*

CASE III.

* May 8th. Robert Tannis applied at the Infirmary with a slight ophthalmia, painful at night; the pupil was hazy and large, and two tubercles projected from its edge. He was put on a mercurial course, and his amendment was marked by the diminution of the tubercles.* The result of the case is not recorded.

* The inflammation in some cases seems to have extended to the other tunics of the eye, and to have affected them in the same

manner as the iris itself. In these instances the eye-ball appears full, the patient is slightly incommoded by pressure on the eye; (I allude to the chronic state, the inflammation having disappeared), the sensibility of the retina is impaired, and in some instances totally destroyed. Is not this the natural termination of the disease when inadequate means are used? The following case, in the left eye, affords an example of it.*

CASE IV.

* Sept. 3d. I observed the following appearances in the eyes of L. H. caused by a violent ophthalmia, which attacked them two years ago. The left eye was tumid and uneasy under pressure, the iris convex and puckered, the pupil small, the capsule slightly opake, the retina insensible—for she was perfectly blind, although the pupil was sufficiently clear to admit some light. In the right eye, the iris was prominent,

convex, and slightly puckered, the pupil of a moderate size, the capsule opake, and vision bad; but the retina was sensible, and no pain was felt when pressure was made on the eye-ball.*

A representation of the destruction of the eye by syphilitic inflammation of the iris, may be seen in plate I.—*See fig.* 2, 3, *and explanation.*

II.—BY SUPPURATION.

* The cornea, when the eye labours under a high degree of inflammation, has sometimes a circular patch of lymph deposited on it, and the inflammation continuing, a little abscess is formed, and is productive of extensive ulceration. An active antiphlogistic treatment will very often prevent suppuration, and then the worst that can happen will be the organization of the lymph, which will constitute a speck much smaller than the cicatrix of the ulcer would

be, if it went into abscess: more frequently, however, the lymph will be absorbed, and no defect will remain.*

When the inflammation pervades the anterior chamber, and affects the surfaces which constitute its parietes, coagulable lymph, it has been said, is effused in greater or less quantities, according to the vigour of the inflammation. It does not seem to be necessary that the lymph should be organized, in order that suppuration of the eye may take place. All the stages of inflammation glide into each other by very insensible degrees. Thus, lymph is deposited in layers, or in granules, each susceptible of being organized, in masses varying in consistence, less and less capable of receiving new vessels, until pure pus is effused. Under a partial suppurative inflammation of the eye, the cornea retains its life, and a sufficient degree of transparency to admit of the accumulation of lymph or pus, or the intermixture of both

in the anterior chamber, being distinctly observed. Soft lymph and pus so exactly correspond in colour, that no distinction can be founded on this circumstance; but the figure of the matter deposited affords a ground of discrimination: the lymph rises in irregular masses, the pus maintains a level. If the entire eye-ball is involved in the suppurative process, its disorganization is effected with incredible rapidity.

III.—BY SLOUGH.

The conjunctiva, like other mucous membranes, is indisposed to the adhesive inflammation; but when the action of its arteries is urged beyond that degree which constitutes congestion, and presents the ordinary form of ophthalmia, the effusion of a puriform fluid takes place, and in the most aggravated state of the inflammation, portions of the conjunctiva and cornea die, and are separated by the sloughing process. The puriform effusion is simply the result

of a high degree of inflammation of the conjunctiva, as a mucous membrane, and is precisely the same in the infant and in the adult. In this metropolis the former is more frequently the subject of it than the latter. From the 25th of March, 1806, to the 31st of December, 1809, the return of the cured of various diseases of the eye at the Infirmary, amounted to six thousand seven hundred and forty-four; of which the relative proportion of adults and children cured of this acute inflammation of the conjunctiva, was one hundred and thirty-three; but that of infants, one hundred and eighty-two. This inflammation is remarkable chiefly for three circumstances—the excessive tumefaction of the conjunctiva, the copious secretion of a puriform fluid, and the changes induced on the cornea. The tumefaction of the conjunctiva of the palpebræ produces a disgusting and alarming appearance: this, indeed, may be followed by a change of structure in that membrane, which may

protract the disease in a chronic state, but the most destructive effect takes place at the junction of the conjunctiva and cornea. The conjunctiva investing the anterior surface of the sclerotica, being connected by a loose reticular texture, admits of tumefaction; but that portion of it which invests the cornea (their union being intimate) must partake of the unyielding nature of the latter texture. How great the stress of the inflammation is at this junction of the tunics, appears first, from the state of chemosis, or circular overlapping of the cornea by the conjunctiva of the sclerotica; and secondly, from the sloughing of portions of the conjunctiva and cornea within this circle. What has already been said on inflammation of the conjunctiva in infants may be applied to the adult: * that the destruction of the eye is accomplished by a mortification of the whole, or of a portion of the cornea, or that vision is impaired, when the disease is less violent, by ill-conditioned ulceration:*—to which may be

added, that the slough commonly extends in the circumference of the cornea, forming a groove which includes a third, a half, three fourths, or even the whole of the cornea. —*See plate* 1, *fig.* 6.

It is worthy of observation, that whilst the conjunctiva is tumid to a degree that exceeds every other form of ophthalmia, and the destruction of the cornea is going on by a succession of sloughs, commencing at its exterior lamella, and extending with more or less rapidity to its most internal, still the anterior chamber, as far as it can be observed, is free from the deposition of coagulable lymph. Indeed, this inflammation has little in common with adhesive inflammation:—on this ground, as well as on the production of sloughs, the author's opinion of its being allied to erysipelatous inflammation might be supported. The truth seems to be, that it is the acute inflammation proper to mucous membranes, and the cornea suffers by contiguity under

the peculiar circumstance above noted. The adhesive inflammation does not appear in the earlier and most dangerous stage of the disease, and the most favourable prognosis is derived from the evidence of its existence in a halo of lymph surrounding the groove left by the separation of the slough, and in the advance of red vessels into the lymph to begin the process of reparation.

In proof of the identity of this inflammation in the infant and adult, the author has left the following observations and cases of its termination in both by slough of the cornea.

* In the acute inflammation of the conjunctiva in adults and infants, which has been termed the purulent ophthalmia, when the disease runs to excess, and is injuring the eye, the cornea becomes obscure at certain places—the sign of approaching death of the part. Supposing the death of the

cornea to be partial, the opake part becomes defined, soon it is slightly elevated, a little transparent line surrounds it, and ultimately, this line marking the ulceration, the opake part is cast off in a slough, leaving the bottom transparent.*

* Sometimes, after the slough has been cast off, the cornea is farther injured by the ulcerative process: if this happens, the breach in the cornea remains clear at the same time that it is enlarging, except the ulcer be filled with the mucous discharge, a circumstance that frequently occurs, and which may readily be ascertained by injecting water on the ulcer; but otherwise it is not difficult to distinguish between mucus and lymph, because the latter cannot be deposited on the ulcer, without a certain portion of it being diffused in the cornea around the ulcer.*

* But it not unfrequently happens that the cornea is destroyed by a succession of

sloughs: in such cases, if a portion of the cornea has already been cast off, instead of a clear transparent surface, a larger portion becomes opake; this being separated, a third portion, still larger, dies, and the anterior chamber is opened.*

* Although the appearance of red vessels in the neighbourhood of an opake portion of the cornea may generally be considered as a mark of healing, yet I have often seen half of the cornea dead, opake, and about to be cast off, with the other half full of red vessels; but then this has had its surface previously sloughy and destroyed. I noted a case in which one hemisphere of the cornea was dusky and elevated, the other hemisphere being covered with red vessels, which seemed to run under the opake part. In the case of Sanderson, recommended to my care, in 1808, by Mr. J. Weston, surgeon, half of the cornea was dead and about to be separated, but not to the last lamina: the other half,

which was full of vessels, had cast off the superficial part just before his application. Ultimately, the whole surface of the cornea sloughed, and at its centre completely through. The breach was filled up from its circumference with lymph which remained opake. On the 20th of October, 1806, a similar case of an infant was brought to me with a sloughy state of the cornea, a fortnight after the inflammation had commenced. The slough had extended nearly through the whole of the right cornea, and red vessels were observed on the rest of that tunic.*

CASE I.

* Aug. 14th, 1806. Ann Stuart, a fortnight old, was attacked seven days ago with inflammation of both eyes. The puriform discharge came on rapidly. This appearance was the first thing particularly noticed by the parents and nurse. The mo-

ther said, that she had observed a redness in the corners of the eye-lids, on the evening preceding the morning in which the puriform discharge was copious, and the palpebræ closed and tumid. On the 14th, the palpebræ were exceedingly swollen, the upper overlapping the lower, and completely covering them. They were too much swollen to admit of examination in the common way. I syringed them, and with Pellier's elevator ascertained that the cornea was not affected. The conjunctiva was as red as scarlet, and granular, resembling a finely injected villous tunic of the intestine; the discharge was yellow, and stained the linen of a straw colour. I freely scarified the conjunctiva of the eye-lids, and injected a solution of alum, in the proportion of two grains to the ounce of water: the bowels being costive, a grain of calomel and a solution of manna were given.

15. The tumefaction of the eye-lids was

much reduced; a portion of the cornea in each eye, but most extensive in the left, was dusky and opake; the bowels were open: the scarification and injection were repeated.

16. The opake portions had much increased, particularly in the left eye, being equal to a third of the cornea; the vascularity of the sclerotica was great: the scarification was repeated, but the injection of alum omitted, and instead of it water was injected twice a day; a leech was applied to each eye, and the solution of manna was given as before.

17. The opake spots of the cornea had not increased; the leeches drew a large quantity of blood, the child was pale and languid, her eye-lids were much reduced, and the discharge was whiter; her bowels were lax: no medicine was given.

18. The inflammation was apparently

greater: leeches were applied, and the aperient was repeated.

19. The wounds made by the leeches bled freely, the child was languid and pale, free from pain, and slept constantly: water was injected as before, and medicine omitted.

20. The eye-lids were much reduced, but the puriform discharge continued, the opake portions of the cornea were elevated and puffy; the bowels were open.

21. The opake portions of the cornea had contracted, a little fissure was observed by the side of the largest, *i. e.* of the left eye; the bowels were natural: medicines were omitted.

22. In the morning, on injecting water into the eyes, the opake substance of the left cornea was separated in a complete mass,

leaving a deep, but nearly clear pit. In the evening, the surface was semi-opake from lymph.

23. Morning. The left cornea was more opake from the deposition of lymph; the eye-lids were reduced nearly to their natural size; the discharge had moderated, and was white.—Evening. The left eye continued in the state reported in the morning. A part of the slough of the right cornea had separated.

24. Morning. The edges of the ulcer of the left cornea had contracted, and were beginning to cicatrize; the discharge was less, and semi-mucous; the right cornea completely cast out its slough.—Evening. The pit left in the right cornea was deep: bowels were regular.

25. Morning. The ulcer of the left cornea was healing; the ulcer of the right cornea had a surface of lymph, and the dis-

charge from the conjunctiva was more viscid.

26. The left eye was healing fast; the right continued nearly in the same state.

27 and 28. The ulcers continued to heal.

30. The left cornea had become more opake, and was enlarging.

Sept. 1. The left cornea protruded more at the part which had sloughed.

9. The solution of alum was injected.

12. Tears were observed in both eyes. The left cornea was clearer, but continued to enlarge and protrude.† The ulcer of the right cornea had nearly healed.

---

† Staphyloma.

20. The puriform discharge had ceased.

CASE II.

* Feb. 7th, 1807.—— Tye, a child, aged two years and a half, was brought to me with an acute ophthalmia. The right conjunctiva was very vascular, and discharged a puriform fluid; the left was slightly inflamed. I scarified the conjunctiva of the right palpebræ freely, prescribed purgatives and small doses of tartarized antimony.

Feb. 10. The right palpebræ were excessively tumid, and the puriform discharge was very great. I examined with difficulty, and found on the cornea an opake spot. Six leeches were applied on the palpebræ, and a dose of jalap was given.

11. The tumefaction was much reduced, the sloughy spot of the cornea was yellow,

and rather elevated. The left eye was much inflamed; the palpebræ were tumid and discharging. Two leeches were applied to the left palpebræ, and she took a dose of jalap.

12. The yellow spot of the right cornea was contracted, and elevated, with a groove around it. The left palpebræ were rather more tumid. Purgatives were ordered.

13. A part of the slough of the right cornea had separated. Her stools were green. I repeated the dose of jalap, and gave cretaceous powders every four hours.

14. The rest of the slough was separating, having a groove around it. The ophthalmia in both eyes was less; the breath sour. A dose of calomel and jalap was ordered.

21. The slough of the right cornea was

entirely cast out. I injected a weak solution of the argentum nitratum, and gave a dose of the diluted sulphuric acid three times a day.

22. The left eye was open, the ulcer of the right cornea healing, and the conjunctiva less tumid. The injection and the acid were repeated.

March 13. Cured. A very small speck remained on the right cornea.*

CASE III.

* Sept. 19, 1806. Thomas Green, a middle-aged man, applied with a violent inflammation of both eyes, and bore in his hand a handkerchief stained of a straw colour with the discharge that issued from the eye-lids; the conjunctiva was highly red and villous, no distinct vessels being visible on that of the palpebræ, and, to a

certain degree, they were obscure on that of the eye-ball; the pain was by no means great: the inflammation came on suddenly, with a sensation of grittiness, five or six days previously to his application. Twelve ounces of blood were taken from his arm, and he was directed to take purging powders of calomel and jalap, on the 19th and 20th.

21. Morning. The cornea of the right eye, which, on the 19th, was slightly opake at three different places, now presented three distinct ulcerated surfaces, clear grooves almost through the cornea. The iris and anterior chamber were perfectly free from change. Four leeches were applied to the right palpebræ and three to the left, and a purging draught was ordered.—Evening. The inflammation of the left conjunctiva had decreased, and the puriform discharge was less. The right remained in the state described in the morning. Four leeches were applied.

22. Morning. Four leeches were applied to the right palpebræ, and a dose of a cathartic mixture was given every four hours.—Evening. Three leeches were applied.

23. The ulcers were apparently filling up.

24. The ulcers were overlapped by the conjunctiva. A purging powder was prescribed for him.

25, 26. The ulcers were filling up: the cathartic was daily repeated.

27. The inflammation was increased in a slight degree: leeches were applied to the palpebræ, and a dose of Ol. ricini was given.—Evening. The inflammation was rather mitigated.

29. One of the pits was a little deeper, others were stationary.

From the 29th of Sept. to the 7th of Oct. the ulcers were stationary and without vigour: during this time he took a laxative every other morning.

Oct. 7. Observing that the pulse was languid and small, and that the process of restoration did not go on with sufficient celerity, I resolved on giving the cinchona.

8. Two drachms of the extractum cinchonæ, dissolved in equal parts of aq. menth. pip. and aq. ammoniæ acet. were taken in twenty-four hours.

10. The same medicine had been continued. The improvement was remarkable and decisive; the ulcers were healing through their whole extent. I increased the extractum cinchonæ to three drachms daily.

11. The ophthalmia had ceased, and

the ulcerated groove was filling up fast.

Nov. 10. The ulcers were quite healed, and his vision was perfect.*

CASE IV.

*June 15, 1809. Sophia Thomas, an adult, was sent to the Infirmary by a Governor. The conjunctivæ were acutely inflamed, and the discharge was puriform. A dose of calomel, a cathartic powder every day, and a weak lotion of cerussa acetata were prescribed.

June 17. The tumefaction of the conjunctivæ and the puriform discharge were very great. Leeches were applied to the palpebræ. The calomel was repeated with a very active cathartic mixture.

20. The inflammation had abated, and the medicines were repeated.

23. There was a chemosis of the left eye, and an ulcerated groove extended more than half around the circle of the cornea. A very strong solution of the extractum cinchonæ, to which the aqua ammoniæ acetatæ was added, was given every three hours. The application of the lotion to the tumid palpebræ was continued.

24. The left eye had sloughed at the inferior part of the cornea, but the right eye was better. The extract was changed for the powder of bark, of which a drachm and a half in water, acidulated with the diluted sulphuric acid, was given every four hours.

26. The mortification of the left cornea was checked, and the puriform discharge of the right eye had ceased. The bark and acid were continued.

27. The left cornea was very sloughy,

but the puriform discharge was subsiding. The medicine was repeated.

July 8. The bark was continued, interposing occasionally a mild laxative (ol. ricini.)

Finally, the left cornea had suffered so much from the sloughing process, that vision was lost. The right eye was cured. The cinchona was continued for a time in small doses twice a day, and a dose of rhubarb and magnesia was occasionally given.*

CASE V.

* Aug. 16, 1809. Sarah Freston, an adult, applied at the Infirmary for an acute ophthalmia. Patches of an opake substance were observed in the circumference of the left cornea, slightly elevated, and apparently sloughy. The cornea was dim. Six-

teen ounces of blood were taken from her arm, and a cathartic was given to her.

18. Ulceration had commenced around the opake spots, and extended very considerably. The same process had commenced on the right cornea. The cinchona was given.

21. The ulcers had now coalesced in the left cornea, so that the central portion of it was surrounded by an ulcerated groove. The right cornea had also cast out its sloughs, but the ulceration did not extend in that eye. The cinchona was continued.

23. The ulceration had stopped. The groove in the left cornea was vascular, and apparently healing, the central part of the cornea being opake. In the right eye also the groove in the cornea was healing. The cinchona was discontinued.

24. The aq. ammon. acet. diluted was

given every six hours, and occasionally a mild laxative (ol. ricini.)

Sept. 5. The medicines had been continued. In the right eye the ulcers had healed, and vision was good. In the left eye almost the whole of the central part of the cornea was opake, the groove was vascular, and undergoing the healing process.*

In cases I. and II. it will be remarked, that the author scarified the conjunctiva; but in his Essay on Inflammation of the Conjunctiva in Infants, written nearly three years after these cases were noted, this practice is condemned. In truth, it was no hasty opinion of its inefficacy that he had adopted: he was experimentally convinced of its evil tendency. Against the practice of scarification he had conceived no prejudice, for although he finally rejected it in acute inflammation of the conjunctiva, yet in the chronic inflammation of that membrane, he

continued occasionally to perform it. The reader is referred to the first chapter of this treatise for the mode of treatment which he ultimately approved and wished to recommend in these infantile cases.

It was his intention to have written a similar essay† on the acute inflammation of the conjunctiva in the adult, in which he would have proved at large, that sloughs, or ill-conditioned ulcers of the cornea, were the most frequent terminations of the dis-

---

† In this Essay, the granular state of the conjunctiva, a change of structure which is occasionally produced by this acute inflammation, and which protracts the disease in its *chronic* form, would have been further considered. He noticed it at the conclusion of Chapter I.; and the treatment which he intended to recommend in the inveterate form of the disease, after having long practised it with success, was excision of the granular portions of the conjunctiva. For this operation he preferred the scissars to the knife, and he prevented the subsequent morbid growth of the conjunctiva by frequently injecting on it a solution of alum, or of the nitrate of silver.

ease; when it proved injurious or fatal to vision. No one could more highly appreciate than himself active depletion, as the means of preventing the effusion of lymph or pus. Many parts of this treatise will afford proof of the bold and successful use of the lancet; and it is not to be interpreted to its prejudice, because, in the *ultimate* stage of an inflammation, which partakes more of the erysipelatous than the phlegmonous character, *i. e.* which, passing over the adhesive and suppurative stages, runs hastily into the gangrenous, he has advised the liberal use of the cinchona. But as this is a practical point of some importance, it may be proper to remark, that this mode of treatment was regulated entirely by the powers of the patient and the appearance of the organ. During the acute inflammation which preceded the slough, he evacuated in proportion to the intensity of the inflammation and the strength of the patient; but when the inflammation lapsed into ill-conditioned ul-

ceration, or more especially into slough, he sustained the prostrate powers of the system by the use of the cinchona, and regulated the function of the bowels only by the gentlest laxatives. Case III. was the first instance in which he ventured on the cinchona, and he has clearly marked the period and the circumstances under which he gave it: *Observing that the pulse was languid and small, and that the process of restoration did not go on with sufficient celerity, I resolved on giving the cinchona.* Such is the rapidity with which this inflammation passes into its destructive stage, that the poor suffering under it seldom apply at a public charity during the period in which the lancet can be used with advantage, or even with safety. It too frequently happens that sloughs or sloughing ulcers have already appeared on the cornea, and it is necessary to commence at once with the cinchona. Cases IV. and V. are added to exemplify the period at which the evacuant should yield to the tonic plan of

treatment. In the former, as soon as the ulcerated groove appeared on the cornea, the cinchona was given: in the latter, the period proper for its use is defined with a degree of accuracy which marked his habit of minute observation, and his judgment as a pathologist. He suspected on the 16th that the opake spots of the cornea were sloughs; but on the 18th he was convinced of it by the breach around them; he therefore gave the cinchona; he continued it on the 21st, whilst the ulceration extended in the form of a groove, but discontinued it on the 23d, when the groove had become vascular, and the opacity of the cornea was then occasioned by lymph deposited around the ulcer. The efforts of art had succeeded. The deposition of lymph and the growth of new vessels afforded proof not only that the sloughing of the cornea was arrested, but that the process of restoration had commenced, and it would not have been prudent to have risked a more vigorous action.

To these remarks on the sloughing of the cornea may be added the following rare observation: * In very old and feeble persons, under the condition of a very moderate redness (one can scarcely say inflammation) of the eye, the cornea becomes turbid and dusky, all its lustre goes away, it appears bedewed with a sort of mucus, as the eye of a dead person: in this state the cornea very soon falls into a state of dissolution. See the cases of Mrs. Deland and Scroop, 1807-8.* The cases referred to cannot be found. He considered that this sort of gangrene bore an analogy to the mortification of the toes in old persons.

IV.—BY ULCERATION.

Ulcers of the cornea constitute the most numerous class of the diseases of the eye. The medical reports of the infirmary for three years and nine months, ending December 31, 1809, present a total of six

thousand seven hundred and forty-four patients cured, of which number one thousand nine hundred and eighty-three were cases of ulcer of the cornea, or of pustules of the conjunctiva, which usually terminate in ulcers of the cornea.

Pustules † of the conjunctiva, aggregated at the margin of the cornea, or appearing separately or successively over any part of its surface, constitute a specific character of strumous ophthalmia, with which the morbid appearances peculiar to that constitution are in various degrees connected.

This form of ophthalmia is produced in large cities by the operation of causes against which poverty cannot guard: namely, an impure atmosphere, improper food, and cold. Of these causes, none is more

---

† The term pustule of the Conjunctiva is usually applied to an appearance which resembles Aphtha in the incipient stage.

productive of strumous ophthalmia, than the want of a pure atmosphere, and therefore the children even of the affluent suffer. The milder cases of this disease yield to a purer atmosphere, and a few doses of calomel and rhubarb, but a too frequent repetition of calomel is injurious. Notwithstanding the unusual sensibility of the eye, denoted by the aversion to light, which the patient strongly expresses; yet, if the inflammation is not acute, and the ulcers are indisposed to heal, the cure is greatly facilitated by injecting on them a solution of nitrate of silver, in the proportion of two grains to an ounce of distilled water. For this purpose a silver syringe is used, and the fluid is directed on the ulcer in a fine and continued stream. But if the inflammation occasions a greater deposition of lymph around the ulcer than the healing process actually requires, general or topical bleeding, according to the age and strength of the patient, and more frequent purging, are attended with great ad-

vantage. In this state of the eye every stimulant application is avoided. The ordinary lotions are a very diluted solution of the superacetate of lead used cold, or a decoction of poppies applied tepid, according to the sensations of the patient.

The condition of the anterior chamber and its parietes, in every case of acute inflammation, demands the most attentive observation. It affords the best means of estimating the danger, and of regulating the mode of treatment. And although, in combination with ulcer of the cornea, lymph, or even pus, should be effused within the chamber, yet an active antiphlogistic treatment will often rescue the organ, the healing process will go on with rapidity, and the power of the absorbents will be manifested, by removing the effused matter to an extent which might have been deemed impossible.

Protrusion of the Iris.—This alarming event, so threatening to the utility and beauty of the organ of vision, is a frequent result of sloughs and ulcers of the cornea. If the anterior chamber be opened simply by the ulcerative process, the efforts of nature may succeed in repairing the injury. Medical aid will only be required to regulate the effusion of lymph, which is necessary for the restoration of the part, by correcting its defect or excess. But it is the sloughing process which chiefly proves destructive, and most speedily effects a breach in the cornea, of which the inevitable consequence is a protrusion of the iris. The intention in the mode of treatment is to arrest the sloughing process, and to excite the adhesive, by which the protruding iris will be united to the breach in the cornea, and its further prolapse will be prevented. With respect to the internal treatment, the remarks on sloughing ulcers have been anticipated by the previous consideration of the termination by slough,

but the local treatment will be illustrated in the following cases. Let it be remarked, however, that the treatment varies with the character of the inflammation.

The annexed cases I. and II. were instances of simple ulceration, and the character of the inflammation was phlegmonous. In these the gentlest depletion sufficed, and nature almost unassisted may be said to have effected the cure. In Case I. this is evident; and in Case II. it is probable that the adhesion of the iris to the edges of the ulcer of the cornea would have been completed without the use of the argentum nitratum. In cases similar in kind, but exceeding these in degree, the depletion must be proportioned to the excess in the effusion of lymph. Of these there are many in which free bleeding from the arm or temporal artery will immediately reduce the action to its salutary degree, and the healing of the ulcer will, from that moment, go on with rapidity.

Cases III. and IV. were examples of slough, or sloughing ulcers of the cornea consequent to acute inflammation of the conjunctiva, and as the former or the phlegmonous were characterised by the effusion of coagulable lymph around them, so the latter or the sloughing ulcers were distinguished by the actual privation of lymph. The efforts of art were intended to change the character of the inflammation, and, by enabling the part to take on the adhesive process, to arrest the disorganization of the eye.

This practical point ought not to be misunderstood. It is the restorative process, flagging and incapable of accomplishing its salutary purpose, which art is endeavouring to assist. The acute inflammation of the conjunctiva which gave rise to this destruction of the cornea, might have been prevented at its accession, or arrested during its early progress by free bleeding, but the mischief is now done, and to persist in active depletion when the cornea is dying and

separating by successive sloughs, and the iris is daily protruding more and more, must be, to say the least of it, a hazardous practice. The point here insisted on is obvious if Cases I. and II. be contrasted with III. and IV. In the former, the iris adhered as soon as it entered the breach of the cornea; but in the latter, for want of lymph, it continued to protrude notwithstanding the effort to increase the general power of the system by the cinchona, until the latter was aided by the local application of a solution of the argentum nitratum.

But the stages of inflammation are never stationary, and in many of these cases the natural powers recover themselves sufficiently to heal the breach in the cornea. In others, notwithstanding the termination by slough, the inflammation, instead of decreasing, as it usually does at this period, continues so acute as to demand the frequent application of leeches to the tumid eye-lids, and the repeated use of purgatives instead of the bark.

CASE I.

* Nov. 10th, 1806. Frances Colbeck had suffered for three weeks an ophthalmia attended with great pain, when, on her application, a small protrusion of the iris was perceived through an ulcer of the cornea. The rest of the iris nearly touched the cornea, and the pupil was of a moderate size. The pain had almost ceased. Only a purge and a lotion of cerussa acetata were ordered.

11th. The protruded iris adhered to the edges of the ulcer, which was evident from the rest of the iris having apparently retired from the cornea: *i. e.* the further escape of the aqueous humour having been prevented by the adhesive process, the anterior chamber had nearly recovered its space.

12th. The ophthalmia was still subsiding, and the anterior chamber was more complete; but the pupil was very contracted.

A purge was ordered, and the extract of belladonna was applied.

22d. A white ring around the base of the prolapsed portion of the iris was the sign of an organized adhesion. The protrusion flattened, the pupil enlarged, and vision improved fast.

Dec. 5th. The prolapse of the iris had flattened to the level of the cornea, and her vision was very good.*

CASE II.

* Oct. 19th, 1806. Elizabeth Oliphant applied at the infirmary for an ophthalmia of ten days duration. Two considerable ulcers were formed on opposite sides of the right cornea. The ulcers were very deep, particularly that which was situated nearest to the inner canthus. Motion of the eyelids excited pungent pain on the surface of the eye-ball. She immediately took six

grains of calomel and a scruple of jalap. A purge without calomel was ordered to be repeated in the morning, and, as a lotion, only a weak solution of the cerussa acetata was used.

22d. The ulcers were deeper, but the pain was less. Two scruples of jalap and crystals of tartar were given.

25th. The ulcers were still deeper, particularly the nearest to the inner canthus. A space of the cornea, deeper than the base of the ulcer and twice its breadth, was nearly opake from lymph. I touched the surface of each with a solution of the argentum nitratum.

27. The iris protruded through the ulcer towards the inner canthus, but adhered and was unattended with pain. The other ulcer was healing.

28th. The process of restoration went on

with rapidity in both. The adhesion of the protruded iris to the edges of the ulcer was established. The pupil was very small and drawn on one side. No laxatives: moderate diet.

Nov. 10th. The cornea around the edge of the protruded iris, and also around the other ulcer, was clearing, and the tumor formed by the iris had diminished. The pupil was enlarged, and she began to see. No medicines.

Nov. 22. The adhesion of the iris to the cornea was perfect, and the protruded portion was so much flattened as to be only a little more elevated than the rest of the cornea. Her vision was very good.

At the time I applied the solution of the argentum nitratum the ulcer was conical, the ulceration through the exterior laminæ being largest, and decreasing towards the interior, where a little vesicle appeared,

protruding and convex. The cornea is always perforated by the ulcer when this appearance takes place.*

CASE III.

* On the 5th of Nov. 1807, Ann Perkins applied, in the advanced stage of an acute ophthalmia, with the right eye lost in consequence of the separation of a slough of the cornea, through which half of the iris was protruding. On the left cornea there was a large ulcer, disposed to spread, its base being convex and transparent. She was ordered to take, in the space of every twenty-four hours, a saline mixture, in which two drachms and a half of the extract of bark were dissolved. A solution of alum was injected over the conjunctiva.

6th. The ulcer had extended, and its base was more convex.

12th. The medicines prescribed on the 5th had been continued.

13th. The iris protruded. The injection of alum was omitted.

To the 21st the medicines as before. The puriform discharge had continued equally from the first—the injection of alum had not at all restrained it. The iris had protruded more and more through the aperture in the cornea, having no adhesion at its base.

22d. A solution of the argentum nitratum (two grains to the ounce of water) was injected at the base of the protruding iris, and over the surface of each eye. In twenty-four hours adhesion at the base of both protrusions had taken place.

25th. The protrusion began to flatten. She continued convalescent.

29th. The puriform discharge had subsided by the daily use of the solution of the argentum nitratum.

Dec. 4th. In the left eye the pupil was of a moderate size, and vision very good. In the right eye the protruding iris had flattened. A little aperture remained in the place of the pupil, but it was not sufficient for distinct vision. The belladonna was daily applied.

18th. A fresh ophthalmia supervened, and the cornea about the protrusion again ulcerated. The solution of the argentum nitratum was injected, and on the 20th the ophthalmia had subsided.*

CASE IV.

* May 14th, 1809. John Cooper applied with four distinct ulcers in a circle near the margin of the cornea. The ulcers were deep, and the discharge was puriform. He

was directed to take half a drachm of bark and five grains of rhubarb every five hours, and to use the lotion of cerussa acetata.

The same remedies were continued to the 20th.

22d. The iris had prolapsed at the most depending ulcer, but seemed to have adhered, for the aqueous humour filled the anterior chamber, and the pupil contracted on exposure to light. The cornea was opake opposite to the pupil, and his vision was dim. The powders were repeated.

24th. The iris had further prolapsed. A solution of the argentum nitratum (in the proportion of two grains to an ounce of distilled water) was injected on the protruded iris. Half a drachm of bark with ten grains of rhubarb was given every six hours.

June 5th. The bark had been regularly continued, and the rhubarb occasionally.

The union of the iris with the breach of the cornea was established.

The bark was continued to the 16th of June, and then omitted. He afterwards took only a scruple of rhubarb with five grains of ginger every other morning.

23d. The eye was cured and he saw.*

CHAPTER V.

ILLUSTRATIONS OF SOME OF THE MORE IMPORTANT CHANGES OF STRUCTURE IN THE EYE.

AMAUROSIS COMBINED WITH CATARACT.†

This organic disease is very rapid in its progress, and produces blindness in the course of a few days: even on the first application of the patient, the loss of vision is

† This form of Amaurosis is intractable. The author has described its ultimate stage, which may easily be distinguished from uncombined cataract; but the incomplete state of the disease is actually confounded with simple opacity of the lens:—A pupil somewhat dilated and still, or

often found to be total. The pupil is dilated, the lens protrudes, the convex iris seems to touch the cornea, the humours of the eye are turbid and dim, especially the

---

or sluggishly contracting over a yellowish lens, even in a strong light, with a tendency in the vessels on the anterior part of the globe to assume a fascicular arrangement, are sufficiently diagnostic of the disease.

There is a second, and, by far, the most common form of Amaurosis, in which the pupil is not only motionless or nearly so, but is also contracted and irregular, and the humours are misty. This likewise seems to be an organic disease, and, although slower in its progress than the former, is generally incurable.

In a third form of Amaurosis, which is commonly called Gutta Serena, *a simple loss of sensibility in the retina, whether it is idiopathic or symptomatic is ascertained by observation on the pupil. A diminution of power is indicated by a sluggish motion in the iris, and even if the pupil does vary, yet it contracts very slowly when exposed to light, and dilates equally slow when the light is withdrawn. When the sensibility is totally exhausted, the pupil is largely and permanently dilated. If only one eye be affected, the motion of the iris seems to be restored whilst both eyes are open to receive the light, but then this activity arises from an association of its motion with the other iris, for if the sound eye be covered, the iris of the blind eye will relapse into its original inactivity.* As a symptomatic affection it is, in recent cases, capable of being cured—first, when it is accompanied with paralysis of the upper eye-lids and a

flushed

crystalline, which becomes tawny or quite opake, the vessels of the sclerotica and conjunctiva are unnaturally large, and run in distinct clusters. The disease remains stationary, as far as I have observed, with occasional pains of the eye or head.

AMAUROSIS PRECEDING THE DISORGANIZATION OF THE EYE, AND THE PROTRUSION OF FUNGI, NOT MALIGNANT IN THEIR NATURE.

CASE I.

In 1807, a girl about ten years old, was brought to the Infirmary, for the purpose

---

flushed face, marking arterial congestion of the encephalon. Secondly, when it arises from the disordered functions of the abdominal viscera, but especially of the alimentary canal or of the uterus. Thirdly, when it attends syphilitic inflammation of the iris. The first is cured by active depletion, by a gentle but long continued mercurial course, and by a very abstemious diet; the second, by restoring the function; the third, by the specific remedy.

of gaining an opinion whether she was blind. Of that there was no question, as the affected eye gave no sign of vision.

This was the state of the eye: The sclerotica was unusually vascular, but not inflamed. The vessels were large and serpentine. The iris, retired from its situation, seemed to be twice as far from the cornea as is natural. The pupil was dilated, and the iris contained many distinct red vessels. The cornea, the aqueous, crystalline, and vitreous humours were at this time transparent. In the course of a few weeks the crystalline became opake; the iris, covered with lymph, and as red as if injected, advanced towards and touched the cornea; shortly, a blue excrescence was thrown out at the superior part of the eye; at that part of the sclerotica which unites with the ciliary ligament. It increased rapidly and became as large as the anterior portion of the globe. This tumour ulcerated, for a long time a thin watery fluid was discharged,

then pus, and lymph which trailed out through the aperture. After some months this aperture closed, the eye-ball, much reduced in bulk, became tranquil, and even retained some vestiges of the cornea, the blue excrescence being totally extinct. During this process there was nothing like acute inflammation, and the pain was very trivial.

CASE II.

In 1809, a boy about three years old, was brought to the Infirmary. On the inferior part of the iris a small patch of lymph was deposited, the pupil was not influenced by it, but varied as usual.† There was no ophthalmia, nor any irritability from expo-

---

† In this case the period at which the retina lost its power is not noted, but as the organic change commenced at the anterior part of the iris, and the pupil varied as usual, it is probable that the Amaurosis did not happen so early as in the former case.

sure of the organ to light. In a fortnight the mass of lymph was so much increased that it occupied the inferior half of the anterior chamber. Now a process of organization commenced in the lymph, and an action analogous to inflammation was set up in the cornea: it became turbid and vascular, the iris and cornea united, a blue mass arose in the situation of the ciliary ligament, which together with the whole of the cornea ulcerated or suppurated, and an ill-conditioned and very luxuriant fungus shot forth. By degrees this fungus diminished, and finally the eye-ball healed.

AMAUROSIS PRECEDING THE DISORGANIZATION OF THE EYE, AND THE PROTRUSION OF MALIGNANT FUNGI.

CASE I.

At the age of nine months, the disease commenced in the left eye of Master E. L.

which when I first saw him, although not inflamed, was vascular and a little enlarged. The iris, in particular, was full of red vessels, and the pupil was very large and fixed. The retina appeared like a concave silver plate, in the posterior part of the eye. This eye was blind, but he suffered little or no pain, and was, in other respects, in good health. At the age of fifteen months the right eye was attacked, and exhibited similar appearances. The left eye was now much changed: the crystalline lens had dropped from its situation, and lay in an opake state at the inferior part of the vitreous humour. About three months before his death, the left eye, which had been for some time very irritable, suddenly enlarged, and began to protrude beyond the eye-lids in the form of a red mass, which ultimately acquired the size of a large apple. About a fortnight before his dissolution, he fell into a state of stupor, with occasional screaming. He soon became frequently convulsed, and died in one of these

fits. I examined the right eye a few days before his death, and observed that what had previously exhibited the appearance of a concave metallic plate, in the situation of the retina, had advanced, and apparently occupied every part behind the iris. It seemed to touch the iris, and the eye gave the appearance of a white cataract with a dilated pupil. This was, however, a deception, as it only occupied the space of the vitreous humour, the crystalline lens being in its natural situation and transparent.

Dissection. The tumour of the left eye being cut in various directions, was found to consist of a hard, fibrous, and vascular mass. None of the original parts of the organ could be distinguished. The head being opened, it was ascertained that the disease had extended in the course of the left optic nerve to the ganglion, the whole of which was converted into a bloody tumour, too soft to be analyzed by the knife, and which melted,

as it were, under the touch, although the examination was made shortly after death. The left optic nerve was sound from the ganglion to its thalamus, and the right, on each side of the ganglion. The ventricles were unnaturally large and full of water.†

CASE II.

Miss G. æt. 35: observed a defect in her vision about the 17th August, 1809. She came under my care, at the recommendation of Dr. Outram, in the beginning of September. She was then blind in the left eye, the pupil of which had its usual black appearance, and was rather more dilated than that of the right eye. Some trifling varia-

---

† Case I. is reprinted from a valuable work on Fungus Hæmatodes by Mr. Wardrop, to whom it was communicated by the author. But Fig. 6. Plate II. which represents the disease of the right eye, was, by permission of Mr. Astley Cooper, engraved from an original drawing taken from the preparation in his collection.

tion was observed in its dimensions when the eye was exposed to a bright light.

Sept. 15. The pupil was fixed, but not much dilated, a tawny substance† covered with a vascular plexus, appeared behind it sufficiently distinct, but was rendered completely evident by enlarging the dimensions of the pupil with the Extract of Belladonna. The mass of disease was mostly situated towards the external canthus, and opposite to this portion the vessels of the sclerotica were turgid and serpentine. The excision of the eye was proposed.

Sept. 18. In the night she was attacked with a most violent paroxysm of pain which commenced during her sleep, from which she was suddenly awakened. Having been also agitated in a dream through apprehension of the expected operation, to which she had consented, a degree of incoherence,

---

† Plate II. Fig. 3, 4.

approaching to delirium, came on. On the 19th, at twelve o'clock, this had subsided, but the severity of the paroxysm was such that her face was covered with large drops of sweat. No appearance of inflammation as yet was present, but the iris was protruded by the increasing tumour, and nearly touched the cornea. In the evening the eye-lids were swollen and the conjunctiva was tumid from serum effused under it. This tumefaction increased, although the pain had subsided, and continued even to the day of the operation; but as this seemed to be merely the effect of the paroxysm, during which the internal diseased mass had acquired so much additional bulk, it was looked on as symptomatic, and not sufficient to contra-indicate the extirpation of the eye.

21st. The operation was performed.†

---

† Mr. Cooper and the Editor were present at the operation, which was supposed to have succeeded, as no unfa-

CASE III.

"In the year 1803, Mrs. L. gradually, and without any pain, or apparent disease, lost the sight of her right eye. About two years after she was attacked with violent pains in that eye, and in the head on the same side; and, from this time, became subject to occasional ophthalmia. In June, 1807, the ophthalmia was extremely severe, attended with violent pain both in the head and right eye. The cornea was considerably opake, the iris was rather contracted, not perfectly circular and quite immove-

---

vourable symptom had occurred previously to the author's death; but she has since been under the care of Mr. Cooper, and the following symptoms were noted by him on the 26th of February, 1811. "Frequent giddiness, pain of the head shooting into the left orbit, from which there is a considerable discharge; a tumour on the eye-lid, several tumours in the breast, three on one side of the abdomen, and one on the other, one at the scrobiculus cordis, and another at the bend of the elbow; shortness of breath, cough, great pain in the right kidney."

able, though the eye was sensible to the action of light. The other eye was also at the same time slightly inflamed. The inflammation and pain in the latter soon subsided, and were removed in the former in about a month; and no more was heard of the patient till the latter end of April, 1808. There was then a very perceptible, and rapidly increasing enlargement of the contents of the orbit of the eye. The cornea had lost all its transparency, and was thickly covered with minute red vessels. The inflammation of the conjunctiva had obscured almost the whole of the sclerotica; but a distinct view of a small segment of its circumference, clearly shewed the globe of the diseased eye to be smaller than that of the sound one. This circumstance, when combined with the great prominence of the diseased eye, furnished strong reason for suspecting that it was constantly pressed upon and protruded by a tumour in the interior part of the orbit. In this state of the disease an operation was

judged the only means of relieving the excruciating pains of the patient, which, though in some degree constant, experienced the most violent exacerbations every evening. On the 9th of January, 1809, the whole contents of the orbit were removed by Mr. Saunders with the greatest care and ability; on this occasion the os unguis was found slightly diseased.

For two days after the operation the patient enjoyed perfect ease. On the third day some pains in the head returned, and though the parts healed well, were considerable, till within the last seven weeks of her life. About that time, after a sleepless night, in which she had experienced much more pain than usual, all pain suddenly left her, and she sunk into a state of mental imbecility, in which she was often unable clearly to distinguish her most intimate acquaintance. Her appetite was excellent and her sleep sound, but more than natural; when awake she was animated with

such high spirits, as generally induced her to address and reply to her friends in a facetious, though not always appropriate, or completely intelligible manner. This state continued till she died on the 11th of July, 1809, in the 77th year of her age."†

CASE IV.

"Mrs. A, at the age of sixty-six, was affected with an ophthalmia of the right eye, preceded by amaurosis. At first view, the disease of the eye bore some resemblance to a cataract; but after an interval, the duration of which is not distinctly recollected, and during which the eye-ball had been more inflamed and painful, its tunics gave way, and a fungus projected anteriorly. From that period

---

† For the particulars of this case, the Editor is indebted to the learned physician under whose direction the operation was performed; and for the morbid appearances to Mr. Cooper, to whom Mr. Saunders gave the preparation. See plate II. fig. 5.

the fungus gradually increased, and she suffered acute but transitory pains, which extended into the head, and to the parts surrounding the eye. She had frequent, and sometimes, considerable hemorrhages from the fungus. Mr. Saunders was consulted; but the stage of the disease admitted only of palliatives. At the age of seventy-three and a half she had become much emaciated, her general complexion was sallow, her pains were aggravated by frequent cough, and she suffered much from want of sleep. The left eye was free from pain, and its vision was perfect. A moveable tumour, situated over the right parotid, projected towards the cheek. The appearance of the fungus at this period is faithfully represented by Plate III. She gradually declined, and died about the termination of her seventy-fourth year."†

† This concise history was obtained by favour of Mr. Weston, who observed the disease from the early period above noted.

CHAPTER VI.

ON THE CONGENITAL CATARACT.

Until the author directed his attention to this interesting subject, no surgeon appears to have given it a distinct consideration, or to have viewed it in any other light than as an occasional variety of the disease, which was to be treated precisely by the same means as the cataract of the adult. The bolder operators who have essayed these means, have found them to be inapplicable to the condition of infancy; and therefore the child thus affected, has been consigned to blindness for at least the first eight years of its existence, as a less evil than the hazard of an operation at so tender an age.

The efforts of nature in disease are seldom stationary, and even when they fail to accomplish the cure, the correctness of the intention may be clearly discerned: thus in the congenital cataract, after the crystalline lens is converted into an opake substance, it is gradually absorbed; and in proportion to the progress of absorption, the anterior lamella of the capsule retires upon the posterior until they form one membrane, which is white, opake, and very elastic. This is the conversion of the lenticular into the capsular cataract: all that is capable of being absorbed nature herself removes, and she only fails to accomplish her purpose, because the capsule cannot be destroyed by this process. It will presently be shewn in what proportion this result occurs, and as the process is commonly completed long before the eighth year, the surgeon, who is now called upon to fulfil his engagement, finds a substance which he will in vain endeavour either to extract or depress.

Although the congenital cataract is a frequent disease, yet its cause is necessarily obscure, because it commences at that period of human existence which seems to preclude the observations of the pathologist. It has been said, that as soon as the lens becomes opake, the absorption of it generally commences; but among the exceptions to this order of events, there is one sufficiently frequent and remarkable to engage our notice. There is a form of the congenital cataract in which the centre of the lens is opake, and its circumference is perfectly transparent. (*See plate* IV. *fig.* 3.) In these cases the lens remains of its natural size, as long as its circumference preserves its transparency, which, if undisturbed, it will do for many years; but as soon as the capsule and lens are penetrated, even with the finest instrument, the opacity proceeds, and is soon completed, sometimes in the space of two days. From this period the process of absorption commences, and the bulk of the lens is diminished with

greater or less rapidity in proportion to the manner in which the wound has been inflicted. Inflammation is thus ascertained to be a cause of cataract. It remains to be observed, whether the congenital cataract may not also be referred to a change of structure which is independent of inflammation, or to actual malformation.

It is a fact not less curious than affecting, that this disease in many instances attacks successively the children of the same parents. From June 1806 to December 1809, sixty cases were submitted to the author's care: of these, two brothers, between whose ages there was a difference of six years, were both affected with congenital cataracts. In a second family, two brothers, twins, became blind with cataracts at the age of twenty-one months, each within a few days of the other. It is remarkable that the four cataracts had precisely the same character. In a third family, a brother and two sisters were born with this disease.

The eldest sister was affected with it only in one eye, the brother and youngest sister in both eyes. In a fourth family, three brothers and a sister had all congenital cataracts. The eyes of the elder brother are represented by *fig.* 3, 4. *plate* IV. The character common to the cataracts of the other three is, with a slight exception, conveyed by *fig.* 3.

The congenital cataract is an opacity either of the lens or its capsule, or of both. The lens is either solid, soft, or fluid; but more frequently it is partially or completely absorbed, and the cataract is capsular. These appearances have been noted in forty-four of the sixty cases, and the proportion is shewn by the annexed Table, in which the corresponding character of congenital cataracts in the eyes of each individual is shewn by the number of double cases. It is still more remarkable that the same character should be preserved in the

cataracts of several children of the same family.

Solid opake lens, with or without opacity of the capsule. Three single, two double cataracts - - - - - 5.

Solid lens, opake in the centre, transparent in the circumference, with capsule in the same state. Five double - - - - - - - 5.

Soft opake lens, with or without opacity of the capsule. Two single, two double - - - 4.

Soft opake lens, with solid nucleus. One single, two double - 3.

Soft opake lens, with dotted capsule, the spots white, the spaces transparent. Two double - - - - 2.

Fluid cataract, with opacity of the capsule. Two single - 2.

Fluid cataract, with opacity of the capsule and closed pupil. Two double - - - 2.

Opake and thickened capsule, the lens being completely absorbed, or the remains of it being thin and squamose. Six single, twelve double - - 18

Opake and thickened capsule, with only a very small nucleus of the lens unabsorbed in the centre. Two single - - - - - 2.

Opake and thickened capsule in the centre, remains of the lens in the circumference. One double - - - 1.

The facts which have been now stated shew that the majority of these cases are capsular cataracts, and that the only difficulty in the way of nature is the capsule. To effect a permanent aperture in the centre of this membrane is the business of art, and applies to every case of congenital cataract which can occur.

Children thus affected possess various degrees of vision. Some indistinctly see external objects, others can discern only bright colours or vivid lights. If the privation of vision be nearly complete, volition, for want of an external object to attract these organs, is not exercised over the muscles belonging to them, and their actions are not associated, but the eye rolls here and there with rapidity, and trembles as it moves.

The excessive mobility of the eye, the unsteadiness of the little patient, the small field for the operation, and the flexibility

of the opake capsule are the difficulties with which the surgeon has to contend. The author overcame them by fixing the eye-ball with Pellier's elevator, controlling the patient, dilating the pupil with the belladonna, and by using a diminutive needle, armed with a cutting edge from its shoulders to its point, and thin enough to penetrate with the most perfect facility. *See plate* VIII. *fig.* 2.

The extract of belladonna, diluted with water to the consistence of cream, is dropped into the eye, or to avoid irritation, the extract itself is smeared over the eye-lid and brow. In the space of half an hour, or rarely exceeding an hour, the pupil is fully dilated, and the application should then be washed from the appendages of the eye. The child must now be placed on a table parallel with a window, from which the eye, that is to be submitted to the operation, is farthest. Four assistants, and in stouter children five, are required to con-

fine the patient. The first fixes the head with reversed hands, the second not only depresses the lower lid with his fore finger, but also receives the chin of the child between his thumb and fore finger, as in a crutch. By this means the play of the head on the breast is prevented, a motion which the child incessantly attempts, and which will very much embarrass the surgeon. The third assistant confines the upper extremities and body; the fourth, the lower extremities. The surgeon, seated on a high chair behind the patient, and taking Pellier's elevator in his left hand, and the author's needle in his right, if he is about to operate on the right eye, or the speculum in his right hand, and the needle in his left, if the operation is to be performed on the left eye, proceeds in the following manner.

ANTERIOR OPERATION.

I.—ON A CAPSULE CONTAINING AN OPAKE LENS.

The surgeon gently introduces the bow of the speculum under the upper eye-lid, his assistant at the same time depressing the lower, and at the moment he is about to pierce the cornea, he fixes the eye by resting the speculum with a moderate pressure on the eye-ball. The position of the operator enables him to do this with perfect safety, and by that consent which can only exist between the hands of the same person, he not only discontinues the pressure, by using the speculum merely as an elevator of the lid, as soon as his purpose is accomplished, but he with facility renews or regulates the pressure at any moment in which it may be required. He penetrates the cornea as near to its junction with the sclerotica as it will admit the flat

surface of the needle to pass, in a direction parallel and close to the iris, without injuring this membrane. (*See plate* VI. *fig.* 4.) When the point of the needle has arrived at the centre of the dilated pupil, he does not boldly plunge it through the capsule into the lens, and perform any depressing motion; it is a material object with him not to injure the vitreous humour or its capsule; neither does he lift the capsule of the lens on the point of the needle, and by forcibly drawing it forward into the anterior chamber, rend it through its whole extent. Such an operation would dislocate the lens, deliver it into the anterior chamber, or leave it projecting in the pupil, and stretching the iris; and, although its soft texture in the child should exempt him from any disorganizing inflammation, the most favourable result will be a permanently dilated iris, deforming the eye. He proceeds with a gentle lateral motion, working with the point and shoulders of the needle only on the surface and centre of the capsule, in

a circumference which does not exceed the natural size of the pupil. His object is *permanently* to destroy this central portion of the capsule: merely to pierce it would not answer his intention, because the adhesive process will speedily close the wound. Having acted upon the centre of the anterior lamella of the capsule to the extent which he wishes, he gently sinks the needle into the body of the lens, and moderately opens its texture. In doing this he may, if he pleases, incline the edge of the needle, by which motion the aqueous humour will escape, and the lens will approach his instrument; but at the same time his field for operating will be diminished by the contraction of the pupil. The needle and speculum are now to be withdrawn, the eye is to be lightly covered, and the patient put to bed.

Inflammation is seldom excited by this operation on the child; but its first approach, marked by pain and unusual red-

ness of the conjunctiva, or serous effusion under it, must immediately be arrested by the application of leeches on the palpebræ, and, in stouter children, by bleeding from the arm, followed by purgatives and a very low diet. Soon after the operation the extract of belladonna should be applied over the eye-brow, to prevent, by a dilatation of the iris, the adhesion of the pupillary margin to the wounded capsule. Nature now performs her part of the cure, and the lens, loosened in its texture, and through the aperture in the capsule subjected to the action of the aqueous humour, is gradually dissolved and absorbed.

A single operation sometimes suffices, and the cure is completed in the space of a few weeks; but if the process does not advance with sufficient rapidity, the operation may be repeated once or oftener, interposing at least a fortnight between each operation. If the adhesive process has counteracted his former operation on the capsule, he will

take care now to effect the permanent aperture in its centre, and he may use greater liberty than at first in opening the texture of the lens.

Some have supposed that the fluid cataract is not only the most frequent, but the most manageable of the congenital cases. Both suppositions are erroneous. It is not only the least common, but the fluid, when extravasated, sometimes excites a hazardous inflammation. In these cases, after puncturing the anterior lamella of the capsule, and discharging its contents into the anterior chamber, it will be prudent to desist for the time, and to guard against inflammation: by this operation the case will be converted into a capsular cataract.

II.—ON AN OPAKE CAPSULE, ITS LENS HAVING BEEN NEARLY OR QUITE ABSORBED.

The surgeon may in this case use the needle with much more freedom than in the

lenticular cataract; but in other respects he proceeds in the manner above described. If any portion of the lens remain as a small nucleus or scale in the centre of the capsule, his efforts will be exclusively directed to detach this portion, by which he will fulfil the intention of the operation, that of effecting a permanent aperture in the centre of the capsule. But although the lens be completely absorbed, and only a capsule of a dense reticulated texture be opposed to the needle, he will still attempt to make a breach in its centre, for if it yields at its circumference, the pupil will be more or less covered with it, and the operation will be imperfect, because this thickened capsule is never absorbed, and the pendulous flap is incapable of presenting a sufficient resistance to the needle to admit of its being removed by a second operation. (*See plate* VI. *fig.* 1, 2, 3.) It sometimes happens that the texture of a capsule, on which the first or second operation has made no impression, will

break up under the repeated touches of the instrument in a subsequent operation. Having fulfilled his principal intention of securing an aperture in the centre, if the capsule yields readily to the instrument, the surgeon during the same operation may lacerate its circumference, to render the pupil clear in its utmost degree of dilatation, always remembering that this liberty ought to be taken only in cases that are capsular. *See plate* V. *fig.* 2. *plate* VI. *fig.* 5, 6.

POSTERIOR OPERATION.

I.—ON A CAPSULE CONTAINING AN OPAKE LENS.

The needle is passed into the eye at the distance of a line behind the junction of the cornea with the sclerotica. If the surgeon chooses to exceed the line, he is still more secure, for the nearer he approaches

the junction of the tunics, the more liable he is to an accident, which will for the time defeat his operation. As the iris is intimately connected with the corpus ciliare, this ligament, if the instrument be entangled in it, will be detached from the sclerotica, to which tunic it has a very slender attachment, and the iris itself will appear† to be torn from its insertion, the blade of the instrument being seen between it and the sclerotica. This accident is rather frequent, but it is never followed by any untoward result, if the instrument be immediately withdrawn. As soon as the needle has penetrated the tunics, he gently depresses its handle so as to direct its point towards the capsule through the thin edge of the lens, and steadily projecting its flat surface between the capsule and lens, he arrives at the centre of the capsule, which he

† The *actual* separation of the iris from the corpus ciliare by this operation is a rare accident: the Editor has only once observed it.

opens, taking the same precaution as in the anterior operation, not to rend it extensively, lest he should díslocate the lens. He now cautiously opens the texture of the lens, and withdraws the needle. In his subsequent operations he will complete the central aperture in the capsule, and then loosen the texture of the lens, suffering the flocculi to fall into the anterior chamber, but not projecting into it any considerable portions of the lens, for the process of its solution and absorption is best accomplished in its natural position.

II.—ON AN OPAKE CAPSULE, ITS LENS HAVING BEEN NEARLY OR QUITE ABSORBED.

In penetrating the eye-ball, the point of the needle must be directed with a sufficient degree of obliquity backwards to avoid the iris, which, in consequence of the absorption of the lens, may have receded more into the posterior chamber. The handle of the instrument must afterwards be depress-

ed, so as to direct the point around any central nucleus or scale of the lens, for the purpose of detaching it. (*See plate* V. *fig.* 1.) If the lens be wholly absorbed, the observations which have already been made on the anterior operation in capsular cases, apply to the present. The flexibility of the capsule is so great, that in attempting to rend its centre with the edge of the needle, a backward or depressing motion is often unavoidable. The surgeon has more power in the posterior than in the anterior operation; but the latter excites less pain and inflammation, and inflicts a slighter, if any injury, on the vitreous humour.

The number of operations which may be necessary to accomplish the cure of a congenital cataract will very much depend on the texture of the capsule and the size of the lens. It is frequently cured by a single operation, more frequently it requires two, often three, sometimes four, but very rarely five. The period of cure will of course de-

pend on the same circumstances. Some are cured in a few days, the greater number in one or two months, in many the process is protracted to three, and in a few to four or even five months.

The following is the total result of the author's operations on the congenital cataract: In sixty patients he succeeded in giving sight to fifty-two. In thirteen of them he operated on single eyes. In two of these, one of whom was an idiot, a pupil of each was completely cleared; but the retina being insensible, the operation was not attempted on the other eyes. In a third the result is not noted, except that he considered it a hopeless case when the operation was tried. A fourth was altogether unmanageable, being not only afflicted with congenital blindness, but also deafness.† In a fifth the eye was lost by sup-

† This youth was of course dumb, and the only inlets to knowledge which his mind could command, were the senses

puration. In the remaining eight he was successful; of these five had each previously lost an eye; one by variola, and four by operations performed by other surgeons; three resulting from attempts to extract. In forty-seven patients he operated on both eyes. In one of these, who was an idiot, no vision was obtained, although a permanent aperture was made in each capsule. In a second the operation was completely

---

senses of touch and smelling. By these he distinguished with facility persons and things. He frequently amused himself with feeling for the door of any room in which he chanced to be, and having taken the key from the lock, he would strike it forcibly against his teeth. Of some indistinct vibrations on the organ of hearing, he probably was thus rendered sensible. He expressed pleasure by leaping, and was encouraged and governed by the touch; but the access to his reason by this sense was too imperfect to control him when his fear was strongly excited by pain and restraint. When therefore the operation was attempted, his struggles could not be overcome by the greatest manual force, and it became necessary to withdraw the instrument. Of a second attempt he seemed to be fully aware, as soon as he was conducted into the room where the first operation had been attempted, and immediately resisted it powerfully.

successful on one eye, but failed in the other by the supervention of acute inflammation, which closed the pupil with lymph. In a third the operation proved unsuccessful in both eyes by the same result as the last—a closed pupil from adhesive inflammation. In a fourth the consequent inflammation passed into suppuration, but the other eye was cured. Two were under care at the time of his death, one of whom was already cured in a single eye. Forty-one were cured in both eyes.

These operations were performed on patients at the following ages: Five, from two to nine months; nine, from thirteen months to two years; four, from two and a half to three years; five, from three and a half to four years; eight, from four to six years; seven, at seven years; eight, from seven to nine; ten, from nine to fifteen; four, from twenty to twenty-eight. Thirty-eight of these patients therefore were at the interdicted ages, but the operation

failed in only two of them: in one, at the age of three years and a half, who had an insensible retina and was an idiot; in the other, at the age of seven years, by adhesive inflammation.

The greatest success attended the operation between the ages of eighteen months and four years; and if any intermediate time be selected, the Editor is inclined to recommend the age of two years. The parts have then attained a degree of resistance which enables the surgeon to operate with greater precision than at an earlier period; yet the capsule has not become so tough and flexible as it does at a later period, after the lens has been more completely absorbed.

But this is not the greatest, although a considerable advantage of an early operation; for in cases in which the patient has no perception of external objects, the muscles acquire such an inveterate habit of

rolling the eye, that for a very long time after the pupil has been cleared by an operation, no voluntary effort can control this irregular motion, nor direct the eye to objects with sufficient precision for the purpose of distinct and useful vision. The retina too by a law common to all the structures of an animal body, for want of being exercised, fades in power. Its sensibility, in many of the cases cured at the ages of four years and under, could not be surpassed in children who had enjoyed vision from birth; but at eight years or even earlier, the sense was evidently less active; at twelve, it was still more dull; and from the age of fifteen and upwards, it was generally very imperfect, and sometimes the mere perception of light remained. But these observations do not apply to those congenital cataracts in which only the centre of the lens and capsule is opake, the circumference being transparent, for in those the retina is exercised by a perception, although an imper-

fect one, of external objects, the motions of the muscles which direct the globe are associated, and an absorption of the lens does not take place: therefore in this variety of the disease, the argument in favour of an early operation is not so much a medical as a moral one—it is preferable for the purposes of education and enjoyment.

On the subject of education it is important to state, that the first step towards it ought to be a certain training of the eye in respect to external objects. When an adult, who had previously enjoyed good vision, is cured of a cataract, he is at once familiar with every object he sees. But when a child who has been blind from birth is cured, the actions of the retina must be frequently repeated to acquire precision and perfection. The Author in a letter on this subject, written only on the day preceding his death, offers the following observations: * To turn the faculty of sight to use, so as to display precise notions

of objects, demands experience, which can only be given by the exercise of vision with considerable intention for a long time. The operation has no power to confer actual knowledge of objects. It only prepares the eye for receiving, and afterwards the intellect must be employed on the objects so received, before any readiness can be acquired. The child therefore must be the object of his parents' attention, and be regularly and diligently exercised about large objects at first, and be taught to know them, then with smaller, and so on by degrees.* The very interesting observations of Cheselden are partly but not wholly confirmed by the progress in vision of some of these cases. He was in every respect fortunate in his subject for observation—a young gentleman, at an intelligent age, with a favourable cataract, a quick retina, and, it may be concluded from his remarks, a steady eye. The majority of the Author's congenital cases were too young for this inquiry, and those at a maturer age had

either too much mobility of the eye, if previously quite blind, or an imperfect acquaintance with objects if the circumference of the capsule and lens were transparent, and consequently very few of them were fit subjects for similar experiments.

The youth on whom Cheselden operated, had no judgment of the shape of bodies, much less of the rotundity or inequality of surfaces as represented by light and shadow; he was ignorant by sight of what he knew by touch; frequent repetition was required to impart the knowledge of any object, and he could at first bear but a little exercise of the retina. These facts are to be referred to the inexperience of the organ, and accord with the above remarks in proving, that sight like touch requires practice for perfection. That objects appeared to him extremely large at first; that he had inadequate conceptions of space and no judgment of distance, in a great measure also resulted from inexperience, frequent comparison

being indispensably necessary to regulate and even to impart these ideas. But that all objects should seem to touch his eyes, cannot be conceived in the sense in which it is meant, however closely the similitude between sight and touch be drawn. An intelligent girl, on whom the operation had been performed at the age of twelve years, was examined respecting this point, after she had acquired a knowledge of distances: she remarked, that at first she actually could not see objects except they were very near to her eyes, and on this account fell over every thing in her way. These patients are indeed short-sighted for some time after the operation, which affords another reason for their slow acquirement of the knowledge of distance.

The child is very awkward in using convex glasses, and extremely unwilling to wear them. The early use of them indeed is inexpedient. Let the eye first gain by practice all that it can naturally acquire,

and the knowledge thus obtained will be more considerable than could have been expected without the aid of a lens. It may be commonly remarked, that the extraordinary employment of the sense of touch is surrendered in proportion to the improvement in vision, but is at first immediately reverted to under any difficulty of finding the object sought.

In the adult, the solubility of the lens had been already proved by Scarpa, Hey, and other distinguished surgeons, but especially by Pott, whose accurate observations first established the fact; not only when it was detached from its capsule and sunk in the vitreous humour, but even whilst it remained in its seat, provided its capsule was opened. After a passage which is quite in point, he adds: "In order to render the fact still more clear, I have sometimes, when I have found the cataract to be of the mixed kind, not attempted depression; but have contented myself with

a free laceration of the capsule, and having turned the needle round and round between my finger and thumb within the body of the crystalline, have left all the parts in their natural situation; in which cases I have hardly ever known them fail of dissolving so entirely as not to leave the smallest vestige of a cataract. In a few instances, where I have had fair opportunity, I have pushed the firm part through the pupil into the anterior chamber, where it has always gradually and perfectly dissolved and disappeared, not producing pain or trouble while such dissolution was accomplishing."

In the child, the preceding observations on the congenital cataract prove that nature herself attempts the cure by the absorption of the lens: on this procedure therefore, as the section of the cornea at so early an age is followed by the most unfavourable result, and depression cannot be accomplished, owing to the texture of the catar-

act, is founded the third operation, of which the essential part, as far as art is concerned, being the proper aperture in the capsule, it may be said to be *an operation on the capsule*, in contradistinction to extraction and depression, which imply principally the removal of the lens from its seat.

If the observations of others on the adult or his own on the child, had failed to indicate to the Author the advantages of the operation on the capsule; accident, that fruitful source of improvement in medical science, would have pointed out to him its utility. The frequent occurrence of penetrating wounds of the cornea, the consequent formation of cataract, and its occasional cure by a natural process resulting from the very mode in which the wound was inflicted, did in fact induce him to perform his anterior operation.

* Feb. 5th, 1808. J. Jaques punctured with a very fine awl the transparent cornea,

pierced the margin of the iris, and the capsule of the crystalline lens. The wound had now produced a cataract, and was attended with a great degree of ophthalmia, and a slight adhesion of the wounded iris to the capsule towards the inner canthus. The inflammation subsided by the usual means, and on the 20th of March, the pupil being dilated with the belladonna, a crucial aperture was observed in the capsule, and the lens itself was becoming flocculent. On the 27th of June he finally presented himself at the Infirmary. The lens was gone and the pupil clear, except at the margin of the adherent point of the iris, where a little of the capsule was seen. He was fitted with proper convex glasses, and saw as well as any one could do after the best operation for the cataract.*

In the child, the operation on the capsule is the only one which is suited to that age. But in the adult, it is to be considered as one of three operations, in the

choice of which surgeons will differ according to the bias which unavoidably results from education or habit. The removal of the opake lens from the axis of vision is not the sole end of the surgeon's skill. This great object of art may be obtained at too high a price, if parts which are essential to the perfection of vision, be permanently injured. By extraction, it is accomplished at the expense of the cornea and iris; by depression, at that of the vitreous humour, and sometimes of the retina. In both, the advantage lies in the expedition of the cure. No one who is competent to judge of the difficulty of perfectly performing either, can for a moment withhold the tribute of his praise from the successful operator. Each has been advocated by surgeons of the highest reputation, and who can doubt the merits of both, when a Pott is opposed to a Richter. In the operation on the capsule, art and nature conjointly proceed in the cure: the part which the latter has to perform is, it is true, slow-

ly accomplished, but its perfection is more than an equivalent for delay. The degrees of vision from that which is perfect to the stage of amaurosis which permits the unhappy sufferer to distinguish only day from night, are so very various, that the merit of this or those operations must ultimately turn, not on the time in which the cure is completed, but on the comparative number, to whom, by the aid of an external lens, perfect vision shall be restored. If the success of the operations could be proved to be equal, even then the preference would be due to that operation which every well educated surgeon can perform, rather than to that which, in the hands of a very few, can accomplish the cure in the shortest period. The Editor, leaving each operation to rest on the basis of its intrinsic merits, proceeds to shew the progressive improvements which the Author made in his operation on the capsule, which purpose will be best answered by a comparative view of its effects on the ordinary ca-

taract of the adult and the congenital cataract of the child.

Aware that, in the adult, he was yielding up an advantage of much importance to the surgeon in declining to attempt the immediate removal of the opake lens from the axis of vision, he resolved to hasten its absorption by subjecting it in the most extensive manner to the action of the aqueous humour. To fulfil this intention, he first operated through the posterior chamber with his larger needle, (*plate* VIII. *fig.* 1.) with which he freely divided the capsule, and cut up the lens in its seat, disregarding its flocculi, or even small pieces which fell in abundance into the anterior chamber, even up to the margin of the pupil. During 1806, and a part of 1807, he practised this operation: the end in view was sooner attained, but frequently at the expense of a dangerous inflammation.

The result of the same operation on the

congenital cataract being in general so very favourable, all its circumstances were carefully reviewed and compared, and its success was found to be connected with the absence of inflammation, or the existence of it in a stage that could be easily controlled. But as the more frequent occurrence of acute inflammation in the adult, could not be attributed to any difference in the mode of operating, the condition of the parts concerned in the operation demanded a strict comparison. In the congenital cataract this striking difference was remarked: either it consisted entirely of capsule, or the lens was relatively soft. In the merely capsular cataract, the iris sustained no pressure after the operation; in the lenticular, the softer lens was broken down by repeated touches with the instrument into fine fragments or flocculi, which, if they remained in the posterior chamber, produced no pressure on the iris; or, if they fell into the anterior chamber, did not in general excite acute inflammation. But in the ordinary cataract

of the adult, the lens was comparatively hard and slow of solution, especially its nucleus or central part, and having lost the support of the anterior lamella of the capsule from the extensive division of that membrane, it was apt to revolve on the instrument, or by a partial dislocation to produce a permanent pressure on the iris. The result of the inquiry was this: In the capsular cataract, inflammation very rarely followed the operation; in the lenticular, the inflammation was in proportion to the irritation or pressure which the iris sustained. It is admitted that inflammation does also occur, independently of pressure, from the extravasation of a fluid cataract, and sometimes simply from the puncture.

The restoration of vision in a shorter period, even to a large proportion of patients, appeared to the Author to be too dearly obtained, if the chance of this blessing was for ever lost to the unhappy few. He would fain have carried the operation to

that perfection which could command success. He had experienced that a permanent aperture could be made in the capsule, that the lens was soluble in proportion to its consistence, as long as it was subjected to the action of the aqueous humour, to which there seemed to be no exception but the ossified lens—a rare disease. In proportion therefore as he could diminish the risk of inflammation, the certainty at which he aimed would be attained. With this view he considerably reduced the size of his needle. (*See plate* VIII. *fig.* 2, 3.) But a still more important change was that which he now made in his manner of using the needle. Proceeding according to the method of performing the posterior operation already described, he made an aperture only in the centre of the capsule, not exceeding the ordinary size of the pupil. Thus whilst the opening was large enough to subject the lens to the action of the aqueous humour, *a sufficient portion of the circumference of the anterior lamella of the cap-*

sule was preserved to confine the lens in its seat. (*See plate* VII. *fig.* 2, 3.) The lens itself he used tenderly, working a little at its centre with a lateral motion of the needle, which is by far the safest method of opening its texture. Sometimes the touch with the instrument was directed backward to avoid the slightest pressure on the iris. He was now content to obtain by several operations what in his first method of proceeding he had gained by two.

The slower process which resulted from this operation, induced the Author to make more free with the anterior lamella of the capsule, and to slit or lacerate it beyond its centre. This was done in the case of *David Davis, but the capsule was rent to a greater extent than it was intended, in consequence of the unsteadiness of the muscles of the globe, and the strong action into which he threw the orbicularis palpebrarum. The unsupported lens revolved on the needle, stretched the iris, and projected in the pupil. It was

carried back with great care, and even partially depressed, so as completely to relieve the iris. It was unfortunate for the man that he was an out-patient, and was conveyed two miles after the operation. Sixteen ounces of blood were taken from his arm before he was dismissed. In the evening the lens had again advanced and pressed the iris, which bulged towards the inner canthus; the pupil was dilated, and he now complained of a heavy dull pain affecting the forehead. The cornea began to slough around its juncture with the sclerotica in forty-two hours, although in the first twenty-four he had lost sixty-four ounces of blood.*

In his subsequent operations, the Author so generally succeeded in guarding against the dislocation of the lens, by confining his operation to the centre of the capsule, that this untoward event never again occurred. In a few patients he even opened the texture of the lens without attempting to effect

the central aperture in the capsule according to his usual practice, and indeed the very principle of his operation; pointing out by this attempt his great desire to leave the lens in its proper seat, reserving the completion of his plan for a second operation, when the lens, reduced in bulk and loosened in texture, should do less injury to the iris. He finally attempted to diminish inflammation by performing his anterior instead of his posterior operation. His method of doing this has been already described with sufficient minuteness, and the preference to this operation is founded on the comparatively slighter injury that results to the eye from a penetrating wound through the cornea.

If the operation on the capsule be performed either on the child or the adult with strict attention to the rules laid down in the former part of this chapter, and to the cautions inculcated in the latter, inflammation will very rarely defeat the intention

of the operator. But if in a case of acute inflammation consequent to the operation, depletion should fail to arrest the adhesive process, and the pupil become closed with lymph, it may be cleared by a repetition of the same operation after the inflammation has been subdued. It is also especially applicable to cases of secondary cataract, as they have been termed; *i. e.* to unsuccessful cases of extraction or depression in consequence of the re-union of the wounded edges of the capsule, and the opacity of its anterior or posterior lamella, as in the following example: * Eliz. Shadbolt, couched seven years ago, applied at the Infirmary on the 23d of June, 1808, for a capsular cataract. The capsule was at least three lines behind the iris, its anterior layer having retracted. The opacity was in the centre, and the black pigment was extended from the ciliary processes to nearly opposite the pupil. The capsule was opened very freely, and she saw directly after the operation. *

In the adult, if the texture of the lens is nearly uniform and permeable, the cure is completed in a space of from three to five months; but if the texture is firmer and the nucleus large, the cure cannot be accomplished in less than seven months. On this account the Author, who thought highly of extraction, and performed this operation with dexterity and success, was inclined to extract the lens when its texture was unusually hard. The Editor cannot assert that he would ultimately have conceded thus much in favour of extraction. It was intended that such decision should result from a very long and impartial trial of both operations. With respect to the softer lens or the capsular cataract, he was satisfied of the superiority of his operation. Surgeons who can extract well, are entitled to make this election; but it is too well known how very limited the success of extraction in general practice has proved, to need in this place further remark.

To those who are inclined to operate on the capsule and lens only in their seat, but who, rejecting the suggestions derived from experience, prefer the bolder operation which the Author first practised, to the slower, but less hazardous one, which he finally approved, some of the following cases will be useful in indicating the extent to which it will sometimes be necessary to carry the means that countervail inflammation.

It may not be improper to close these observations by declaring that the excellence of the Author's operation does not rest merely on the evidence of the Editor. Mr. Travers, since he was appointed Surgeon of the Infirmary in March 1810, has cured by this operation forty-seven patients, and although many of these were cases of congenital cataract, the majority were cases of ordinary cataract in the adult, in whom the lens was frequently of a firm texture.

CASE I.

* On the 19th June, 1806, I operated with the large needle (*plate* VIII. *fig.* 1.) on the right eye of Neale, a boy seven years old, affected with congenital cataracts. I cut the capsule and the lens freely, and left the whole in their situation. In the evening he complained of slight pain, and in the morning the eye was inflamed. Four ounces of blood were taken from his arm, and eight leeches were applied to the eyelids.

22d. The inflammation had moderated, but the iris was much dilated. In three weeks the cataract was absorbed, and a large portion of the pupil was clear.

Sept. 1st. The pupil was perfectly clear and had returned to its natural size, the iris having recovered its action very gradually.

July 7th. I operated on his left eye. On lacerating the capsule, a semi-fluid substance filled the anterior chamber.

8th. The eye was inflamed. He was twice bled in the course of this day, and leeches were applied to the eye-lids.

10th. The nucleus of the lens was in the anterior chamber, and the cornea was opake.

12th. The semi-fluid portion of the cataract had disappeared. The capsule was retracted and irregularly opake like net-work. The pupil was so largely dilated that the iris was almost invisible.

Sept. 19th. Very little opacity remained, the iris was gradually returning to its proper state, and his vision was good in both eyes.*

CASE II.

* Fanny Crawford, at the age of thirteen, was admitted into the Infirmary for congenital cataracts. Each lens was opake in its centre, but transparent in its circumference, and of its natural size.

Aug. 18th, 1807. I operated on the left eye, and very freely opened the capsule and the texture of the lens, leaving the latter projecting towards the cornea. In the evening she felt great pain, which was increased on exposure to light; the pupil was rigidly contracted around a small portion of the lens, which projected through it, and the iris was convex at many places, having contracted over the projecting portions of the lens. Eight ounces of blood were taken from her arm, and five grains of calomel were given to her.

19th. The pain had ceased, but the eye

was irritable, and the iris and pupil remained in the state last described. The inflammation was subdued by taking away eleven ounces of blood, which occasioned her to faint, and by purging her.

24th. The detached capsule adhered to the iris at two points.

30th. The operation was repeated on the left eye, but the motions of the needle were directed backwards. The capsule was found to be more tough than before, and the needle was rather freely used. In the evening she suffered considerable pain in the eye. Eight ounces of blood were taken from her arm, and she was briskly purged with calomel and magnesia vitriolata.

31st. The eye was inflamed, the iris adhered towards the external canthus, and the pupil was contracted around a projecting portion of the lens. I opened the left temporal artery, and she lost eight ounces of

blood. She presently afterwards bore the light without shrinking or watering of the eye.

Sept. 1st. She had no pain, the pupil contracted and dilated, the extent of the adhesion was not visible in consequence of the numerous particles of the lens in the anterior chamber, rendering the whole obscure. She took a scruple of jalap, and afterwards a quarter of a grain of tartarized antimony every four hours.

5th. The absorption of the lens was going on fast.

13th. The operation was repeated, and no inflammation succeeded.

Oct. 10th. By a fourth operation a large aperture was made in the capsule, and she saw.

11th. She had no inflammation. The aperture was occupied by flocculi.

22d. No inflammation resulted from a fifth operation, by which the left eye was perfectly cured, and the pupil left regular.

Nov. 8th. The operation was performed on the right eye: I opened the capsule extensively, loosened the texture of the whole lens, and projected a considerable quantity of its particles into the anterior chamber.

9th. During the night more of the lens entered the anterior chamber. The ophthalmia was considerable. She lost eight ounces of blood from the arm, and the same quantity on the following day.

11th. The inflammation had ceased. The iris bulged a little, but the pupil was free.

Dec. 5. The operation was repeated without any unfavourable result.

Jan. 1st, 1808. The right eye was also perfectly cured.*

CASE III.

* Eliz. Augier, born blind with cataracts, was submitted to the operation at the age of two years and two months.

Nov. 8th, 1807. I operated on both eyes. The cataracts were chiefly membranous and tough. The capsule was opened extensively in the left eye, and little less in the right.

21st. The right capsule had reunited, but a considerable absorption of its contents had taken place. In the left eye the remains of the lens was concave, and

the rent in the capsule had not coalesced. The operations were repeated. In the right eye I opened the capsule extensively, but exactly in its centre. A large portion of it was very dense and opake. In the left, a small nucleus was detached and pushed through the pupil, leaving it clear.

22d. The pupil of the left eye continued clear, and the small nucleus lay in the anterior chamber without exciting ophthalmia. The right capsule remained open.

28th. No ophthalmia followed the operations. She saw with the right eye, although in the upper part of the pupil a large portion of the capsule remained. The nucleus in the left wasted fast.

Dec. 6th. The operation was repeated on the right eye, and the lower part of the capsule was lacerated, but she disengaged her head, and I was obliged to withdraw the

needle without detaching the capsule to the extent which I had intended.

7th. The inflammation was slight, but some adhesions of the capsule to the iris were about to take place. The belladonna was applied.

12th. An absorption of all the lower part of the cataract in the right eye had taken place. The nucleus in the anterior chamber of the left eye was almost gone.

Jan. 4, 1808. Both eyes were cured.*†

CASE IV.

* On the 18th of Feb. 1807, at three o'clock *p. m.* I operated on both eyes of Smith.‡

---

† The Editor has seen this little patient in the course of the present year (1811) and her vision is perfect.

‡ Smith was a robust countryman. The operation was performed with the large needle, and the Author freely divided the texture of the capsule and lens.

The cataract in the left eye was particularly hard. He was much affected by the operation with tremors and nausea. At half past ten at night he had the following symptoms: Pain of the head intense, respiration much affected, nausea, eructation, occasional vomiting, pulse full and rather hard. Twenty-six ounces of blood were taken from his arm: an ounce and a half of magnesia vitriolata was given to him, but was rejected by vomiting in half an hour. At half past one he was rather easier. I examined his eyes: both pupils were much dilated, and did not contract on exposure to light.

19th. He had no sleep during the night, and at half past seven in the morning the pain was rather greater; all the other symptoms remained. The vascularity of the sclerotica was great. I opened the left temporal artery, and drew off forty-eight ounces of blood. He was faint and easier. After taking eight drops of tincture of opium to

compose his stomach he dozed for two hours. At half past ten he took six grains of calomel; and at half past one, four spoonfuls of a solution of magnesia vitriolata. At three the medicine had not operated. Four grains of calomel were repeated, with an ounce of ol. ricini. At half past ten at night the pulse had risen; no stools had been obtained, and he had frequent nausea. Thirty-three ounces of blood were taken from his arm. He fainted. After this evacuation he remained low and tranquil, and his respiration became natural; his eyes were not more inflamed than they had been in the morning; both pupils were dilated.

20th. He had slept two hours during the night, the pain was less, but the vascularity of the sclerotica was still great, especially of the right eye: the nausea had ceased. He took ten grains of calomel with two scruples of the cathartic extract, and was purged four

times. In the evening he was tranquil, the pain was nearly gone, except a little in the right eye.

21st. The right eye was very vascular and a little painful. He was purged very much by three grains of calomel and half a drachm of cathartic extract. In the evening his tongue was furred and dry, the right eye still painful, but not more so than in the morning. He was ordered to dilute. I purged him simply every day from the 21st of Feb. to the 2d of March, when the pain increased. Two grains of calomel with one grain of opium and one of antimonial powder were given at night, and a purging powder in the morning.

3d. The pain was less. He had been able for four days past to distinguish the hands of my watch. The medicine was repeated.

5th. The inflammation had subsided in

the left eye, and was much reduced in the right. The medicine was continued.

15th. For several days he had been able to see with the right eye, although it was still inflamed. The ophthalmia had not relapsed in the left, in which absorption went on fast, and the lens was pellucid in its centre.

31st. There was still a considerable ophthalmia of the right eye. The left remained free from inflammation, but the pupil was contracting, and the iris adhered.

April 9th. The left iris adhered very much to the capsule, which was tough. I cut the capsule with the needle opposite to the pupil, but could not detach the adhesions.

June 5th. The cataract of the right eye was gone, but the cornea from continued

inflammation was cloudy, and the iris was dilated.

7th. I operated on the left eye. The pupil was irregular, but not very small. Two points of the iris projected towards the centre of the pupil, and were firmly fixed. I operated with the small needle, and detached the points of adhesion; the pupil dilated after the operation, and recovered its circular form.

9th. He felt no pain, but the eye was very red and apparently inflamed. He saw large objects.

24th. He was restored to perfect vision. For distant objects his right eye required a lens of three and a half inches focus; his left, of four and a half; for near objects, each eye a lens of two.*

CASE V.

* March 16, 1807. I operated on the right eye of Mrs. Clements in the usual mode, at eleven o'clock. In the evening she complained of a good deal of pain. I examined the eye, but there was no inflammation. Twenty drops of tincture of opium were given to her.

17th. She had slight ophthalmia, the pain was still sharp, the pupil contracted, the eye hurt by light, the pulse languid, with some prostration of strength.

18th. The ophthalmia was rather acute. She was ordered to take a solution of magnesia vitriolata until she was freely purged.

19th. The ophthalmia was still acute. The salts were continued,

20th. The inflammation was less.

31st. The inflammation had ceased. The pupil dilated and contracted with great freedom, the cataract was much reduced, but still blocked the pupil. In this case the pain was the indication of the ophthalmia about to succeed; perhaps it is always so, and the apparent prostration of strength ought to be disregarded.

April 5th. The capsule having coalesced, and no farther absorption going on, I repeated the operation, and found the iris adherent at one point. I tore the capsule very freely, and left a good deal of the pupil clear. In the evening the pain was trivial.

9th. The capsule had not re-united, and she saw large objects.

April 25. Her vision was perfectly re-

stored. Focus for distant objects, three inches and a half; for near objects, two and five-eighths.*†

These cases are intended to exemplify the operation which the Author performed during the year 1806 and the greater part of 1807. This operation was not commonly followed by a hazardous inflammation, if either the lens was very permeable and favourable for solution, or the cataract was capsular; and the cure was unquestionably more speedily accomplished by it. In Case V. vision was useful in little more than three weeks, and perfect in six. But when the lens is of a firmer consistence, Cases II. and IV. may serve as instances of the acute inflammation which is apt to supervene, and which cannot always be prevented from terminating in a closed pupil in consequence of the effusion of coagulable

† The communications between asterisks in this chapter are taken from the notes of the Author.

lymph. The preference therefore to the more cautious operation on the centre of the capsule is justly founded, for in proportion as the certainty of the cure increases, the time in which it can be accomplished becomes a subordinate consideration. The fifth, sixth, and seventh plates are added to illustrate more fully than cases could do this latter method, viz. his anterior and posterior operations on the capsule.

PLATE 1.

FIG.1.

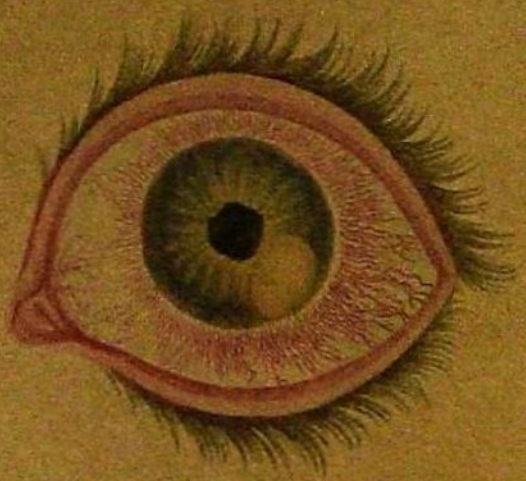

FIG.4.

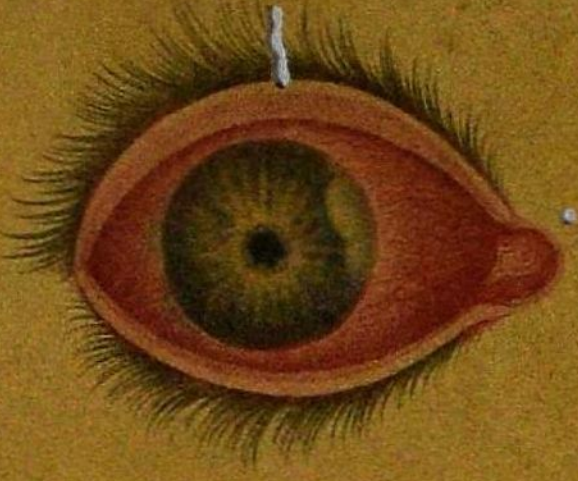

FIG.2.

FIG.5.

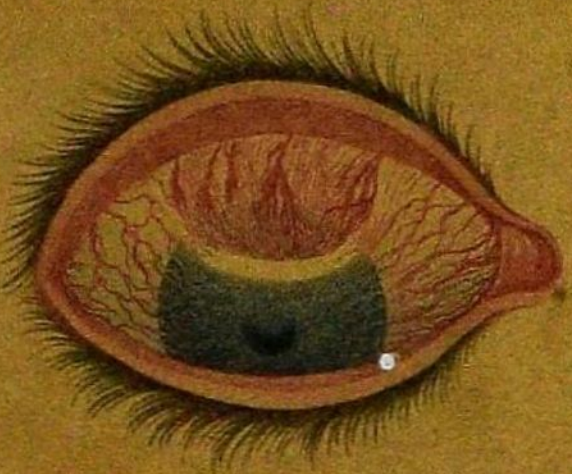

FIG.3.

FIG.6.

Drawn by H. Thomson *Engraved by J. Stewart*

Published by Longman, Hurst, Rees, Orme & Brown March 1 1811.

EXPLANATION

OF

THE PLATES.

PLATE I.

Fig. 1. Shews the early and curable stage of syphilitic inflammation of the iris. A zone of red vessels is seen around the junction of the cornea and sclerotica, the pupil is very irregular, and a tubercle of lymph, of a yellowish colour, appears on the iris towards the external canthus. The vascular zone is characteristic of the early stage of inflammation of the iris, but is common both to the simple and syphilitic forms of the disease, therefore it is mentioned among the signs of the former, (see page 22,) but is

not included in the diagnosis of the latter: (see page 64.) The female from whom this drawing was made, applied at the Infirmary nearly blind under the secondary symptoms of syphilis. Although she was delicate, and an unfavourable subject for depletion, her temporal artery was divided, and she was put on a full course of mercury. In a fortnight the lymph was absorbed, and the ophthalmia had apparently ceased. Supposing herself cured, she ceased to attend the Infirmary, but returned in two or three weeks with her eye in the state which is represented by this coloured engraving. A mercurial course again arrested the disease.

Fig. 2. Shews the advanced and incurable stage of syphilitic inflammation of the iris, combined with amaurosis. The inflammation is diffused over the external tunics, the pupil is dilated and is not in the centre of the iris, and three tubercles of organized lymph are seen on the iris

towards the external canthus. It was taken from the eye of a man affected with secondary symptoms of syphilis, who applied at the Infirmary in this stage of the ophthalmia, which terminated in the disorganization of the eye, although he submitted to a full course of mercury. The treatment happily preserved his other eye, on which the zone of red vessels had already appeared.

Fig. 3. Shews the termination of the disease represented by *fig.* 2. The iris and cornea are in contact, both of these tunics are very much diminished and obscured, the sclerotica is very tumid and irregular on its surface, as if ready to burst at many points. The man suffered much pain in his head, and his health rapidly declined. On a consultation it was resolved to make a free incision through the tunics of the eye. This was done by Mr. Travers. No discharge attended the operation. Poultices were ap-

plied, the eye gradually subsided, became tranquil, and healed.

The following figures in this plate are taken from drawings which were executed under the author's direction, but he has not left any reference to the cases.

Fig. 4. Shews a puckered iris, a pupil contracted and adherent to the capsule, which is becoming opake, a deposition of lymph on the iris towards the internal canthus, and a diffused inflammation of the conjunctiva and sclerotica.

Fig. 5. Illustrates the adhesive inflammation of the cornea. The conjunctiva and sclerotica are partially inflamed; a considerable deposition of lymph, in the form of a crescent, is seen between the conjunctiva and anterior lamella of the cornea, with a halo of lymph extending beyond it and eclipsing the greater part of

the pupil; a large cluster of vessels, in a state of congestion, are seen in the act of organizing the lymph which they had previously effused. See the first section of Chapter IV.

Fig. 6. Illustrates the sloughing of the cornea. The conjunctiva is acutely inflamed; a considerable portion of the cornea, at its junction with the sclerotica towards the inner canthus, has sloughed, and left a deep ulcer in the form of a groove; and the ragged edge of the cornea has a faint halo of lymph, which marks the commencement of a salutary action. Below this ulcer another portion of the margin of the cornea is dead. This portion is opake, its colour a dusky white inclining to yellow, a faint line of separation on either side of it marks the ulcerative process by which it is about to be thrown off. See the third section of Chapter IV.

PLATE II.

Fig. 1. and 2. Represent the upper eyelid in its closed and open state after the excision of the tarsus, according to the method recommended in Chapter III. for the cure of inveterate inversion.

Fig. 3. and 4. Represent the external appearance, and internal structure of the eye of Miss G. See her case in Chapter V. In the former the pupil is oblong and dilated, and a tawny substance is seen posterior to the lens. In the latter the section was carried through the centre of the optic nerve, tunics, and humours. The line of the sclerotic coat is perfect except at a single point, where it is slightly elevated by the extension of the disease towards the exterior of the globe. The insinuation of the disease between the

FIG. 1.

FIG. 2.

FIG. 3

FIG. 4.

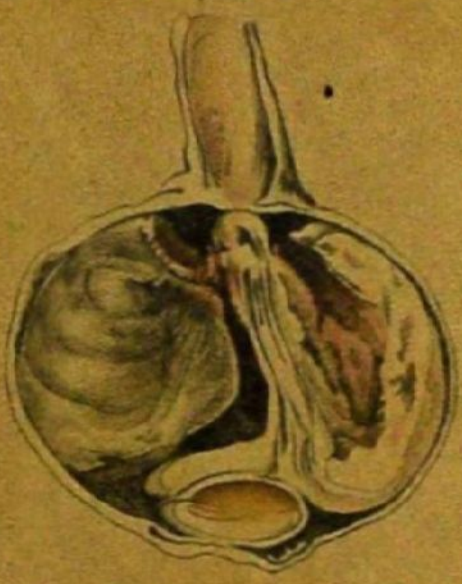

FIG. 5.

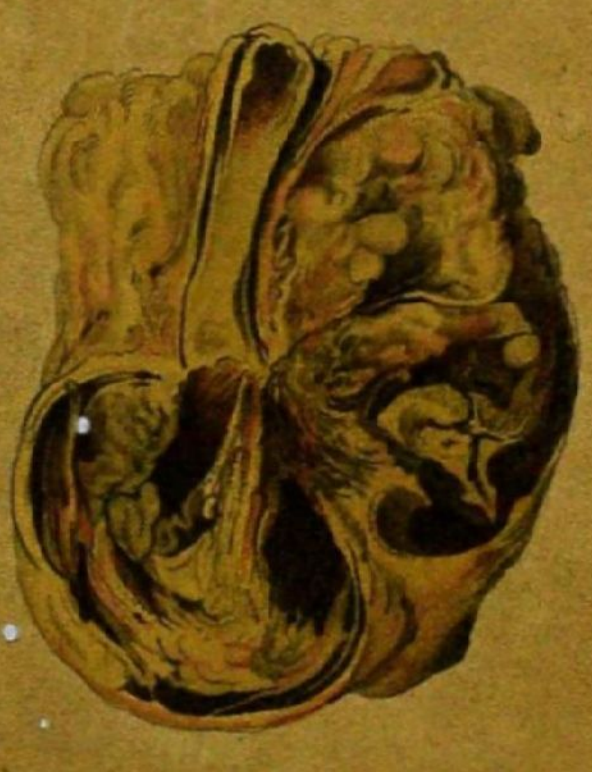

FIG. 6.

Drawn by H. Thomson. Engraved by J. Stuart.

Published by Longman Hurst Rees Orme & Brown March 1st 1811.

fibres of the sclerotica was perhaps too minute for delineation. This is the only part of the coloured engraving which does not perfectly represent the preparation. "The crystalline humour retains its usual situation, but the vitreous humour and retina occupy only one half of the globe of the eye, being displaced by the substance which grew on the opposite side of the interior of the globe, and constituted the disease for which the organ had been removed. Its size is large enough to occupy nearly one half of the common seat of the vitreous humour. It seemed to be composed of a yellow coloured coagulable lymph streaked with black, and to have originated from the inner part of the sclerotica, for the choroid coat was ascertained by dissection to quit the sclerotica and pass on the inner side of the tumour. The sclerotic coat at the part at which the tumour adhered most firmly was partially absorbed, and a portion of the disease, about the size of the head of a pin, had insinuated itself be-

tween its fibres, and was ready to appear on the outside of the sclerotica. The retina is compressed into the centre by the tumour on one side, and the vitreous humour on the other, which is not diseased, but is coagulated by the spirits of wine in which the eye had been previously immersed. The shrinking of the cornea, the tints of the lens, and optic nerve, are also the effects of the spirits of wine."

Fig. 5. Shews a more advanced stage of the same disease, by which the different parts of the organ are altered and confused. It represents a section of the eye of Mrs. L. whose case is related in Chapter V. At the upper part of the figure, the optic nerve is seen in the centre of diseased adipose substance, with a discoloration of its medulla at the dissevered extremity. From the junction of the optic nerve and eye-ball the line of the sclerotic coat may be followed on one side of the figure; but on the other, " it appears that the sclerotic coat had ul-

cerated near to the entrance of the optic nerve, and that the disease had communicated itself generally to the adipose membrane in which the eye is embedded. From the fat it had extended to the dura-matral covering of the optic nerve, and the nerve itself had at that part taken on a similar diseased action, so that an insulated disease had been thus produced in the nerve about three-quarters of an inch from the eye, the nerve remaining sound between this spot and the posterior part of the globe."

Fig. 6. Represents the disease of the right eye of Master E. L. the history of which is given in Chapter V. "The tumour, which differs from the other cases in its seat, texture, and colour, is formed of the tunica aranea, vitreous and crystalline humours, enclosed in the retina, and of a soft coagulable lymph disposed in small lobes."†

---

† The description of appearances marked by inverted commas was obligingly communicated by Mr. Astley Cooper, who dissected the diseased eyes.

PLATE III.

This plate is intended to represent an external and ultimate appearance of the disease, which has been shewn in its internal and incipient stage in *fig*. 4. *plate* II. The upper eye-lid is much enlarged, and partially everted by a fungus, the surface of which is irregular, somewhat fissured, and stained with blood. The colour of the fungus varies; some portions of its surface are florid and luxuriant; others, especially the most depending, are in a state of decay.

A section of this fungus and of the contents of the orbit would have afforded a more interesting, because a more characteristic view of the disease; but an examination after death was not permitted. See the case of Mrs. A. in Chapter V.

PLATE III

Drawn by H. Thomson

Engraved by J. Stewart

Published by Longman, Hurst, Rees, Orme & Brown March 1st 1811.

PLATE IV

FIG. 1.

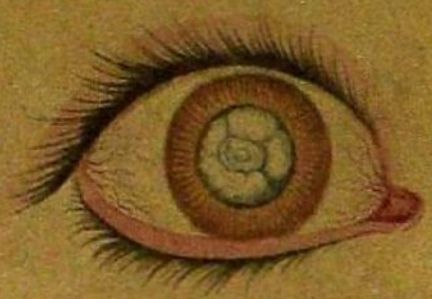

FIG. 2.

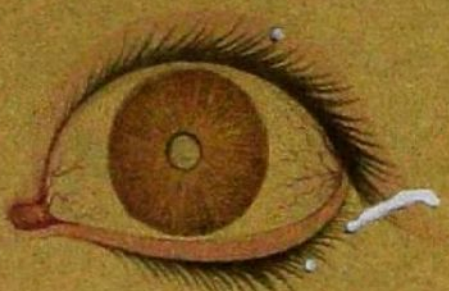

FIG. 3.

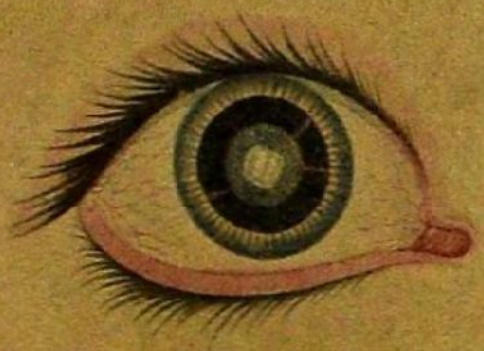

FIG. 4.

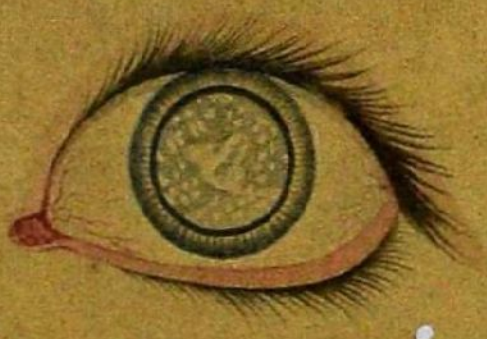

FIG. 5.

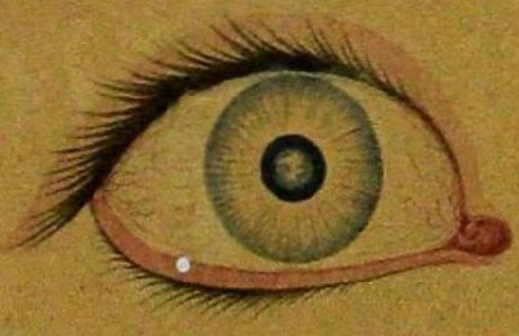

FIG. 6.

Drawn by H. Thomson. Engraved by J. Stewart

Published by Longman, Hurst, Rees, Orme & Brown March 1st 1811.

PLATE IV.

This plate affords a view of some of the most remarkable varieties of the congenital cataract. The dilated pupils in several of the figures manifest the advantage of the application of the belladonna in exposing a larger surface of the cataract, by which its character is ascertained, and the operation on the capsule is performed with greater precision. Compare *fig.* 1, in which the pupil is dilated, with *fig.* 2, which shews the state of the pupil previous to the application of the belladonna. The former represents an opake capsule, containing only the remains of a lens, which is thin and squamose; the latter, a purely capsular cataract, the lens having been completely absorbed.

Fig. 3. Shews a lens of which the centre is opake, but the circumference is transpa-

rent, with the exception of three opake radiated lines, which seem to indicate some variety in the configuration of the two parts, and also render it probable that this form of cataract may be referred to a change of structure which is independent of inflammation. The very white spot in the centre of this figure represents an opacity of the capsule. *Fig.* 5. shews the same eye with the pupil undilated.

A fluid or milky cataract, with partial opacities of the capsule, is shewn by *fig.* 4, and the state of the capsule, after its fluid contents had escaped into the anterior chamber by simple puncture, and had been absorbed, is more clearly represented by *fig.* 6.

FIG. 1.

FIG. 2.

FIG. 3.



Drawn by H. Thomson. *Engraved by J. Stewart.*

Published by Longman, Hurst, Rees, Orme, & Brown. March 1.1811.

PLATE V.

This plate illustrates some points in the operation on the capsule, which relate to the use of the needle. In *fig.* 1, which is chiefly a capsular cataract, the needle has penetrated the capsule at the outer part of a defined nucleus, which may indicate the point of the capsule that ought to be pierced for the purpose of making the central aperture, as the boundary of the nucleus does the extent which is to be dissevered or fretted away (if possible in the first operation) to render that aperture permanent. The introduction of the needle in this figure is in the manner of the posterior operation; but in *fig.* 2, after that of the anterior operation, by which some progress in the opening of the centre of the capsule is represented. The point of the needle is too much out of view, and should be acting rather more on the centre of the capsule.

In *fig.* 2. the cataract is purely capsular and congenital; but in *fig.* 3. it is purely lenticular, and a form of the ordinary cataract of the adult, which is the best adapted for the operation on the capsule. If the tint of the lens be somewhat yellow, and especially if it also incline to brown, its texture is much firmer, and its solution is more slowly effected. The needle is here introduced for the purpose of shewing that in the posterior operation it is made to penetrate the very edge of the lens, and to appear under the capsule just within the dilated margin of the pupil. This is done merely to avoid the entanglement of the instrument in the centre of the lens, which interferes with the intended precision and gentleness of the operation on the capsule. The needle is to be steadily passed between the lens and the capsule, and the latter opened at its centre.

The eyes here represented were cured by Mr. Travers.

PLATE VI.

FIG. 1.

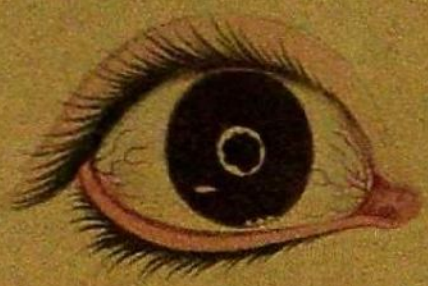

FIG. 2.

FIG. 3.

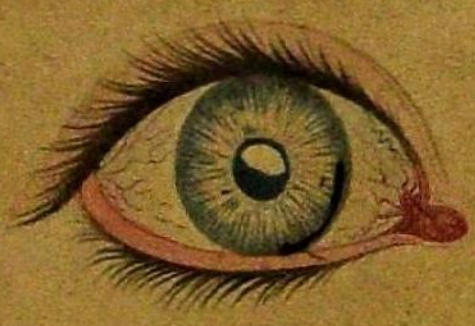

FIG. 4.

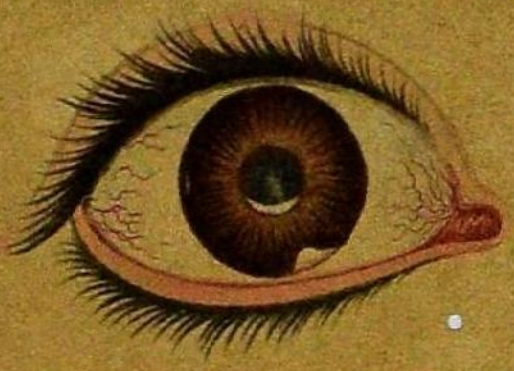

FIG. 5.

FIG. 6.

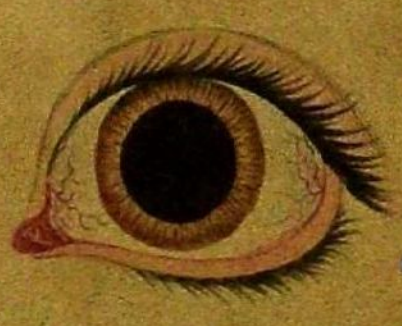

Drawn by H. Thomson. *Engraved by J. Stewart.*

Published by Longman, Hurst, Rees, Orme, & Brown, March 1.1811.

PLATE VI.

This plate shews the effect of the operation on the capsule in the congenital cataract. In *fig.* 1. 2. which represent the eyes of Chapple, a girl twelve years old, the central aperture was effected in both eyes, and as the cataract was capsular, the aperture would have been enlarged if the capsule had not been so tough as to render it impossible. This thickened capsule is incapable of being dissolved or absorbed. A margin of it behind the pupil, and some portions of it which were detached into the anterior chamber, presented the same appearance at the end of three years which they did immediately after the operation. In *fig.* 3. representing one of the eyes of Miss F. the central aperture was attempted, but the intention was imperfectly accomplished, because the inferior half of the capsule yielded at its circumference also, and thus

the superior portion was left pendulous and incapable of being removed by any subsequent operation. In this patient the disadvantage of a protracted operation was very manifest. It was performed on both eyes at the age of ten years, but such a tremulous motion of them had been acquired, that she cannot even now, although three years have elapsed since she was cured, direct her eyes to objects with sufficient precision. In *fig.* 4. not only has the central aperture been effected, but the pupil has been cleared, except at its inferior margin, to which a small portion of the capsule, in the form of a crescent, adheres. It was engraved after a drawing made from the eye of Miss D. This young lady had a cataract of some duration from a puncture with a fork. Two opake spots of the cornea, one over the pupil, the other below, at the junction of the cornea and sclerotica, mark where its points entered. A small opake spot of the cornea towards the external canthus was the part at which the needle

was introduced. The eye was cured by a single operation, performed only ten days before the author's death. On cases of cataract of one eye, the other being perfect, whether the cataract was primary, or arose from injury, he operated with the happiest results. In *fig.* 5, 6, not a trace of the capsule remains; even when the pupil is dilated in its utmost degree, as in *fig.* 6, by the belladonna. This beautiful operation was performed, at the age of three years, on Jane Yardley, who had been blind from birth. The cataract consisted of the thin remains of an opake lens, yielding in its texture, and contained in a capsule also thin and yielding. Each eye was cured by a single operation, performed on the same day. The cataract was first broken up in the centre, and then from the circumference of the pupil. She had vision in five days, saw very well in seventeen, and perfectly in forty-eight; when both pupils were as clear as they are represented by these figures.

PLATE VII.

Fig. 1. Presents a form of cataract which is rare, except in patients who are born with the disease. But this was not a congenital case. The young woman, whose eyes are represented by this coloured engraving, for both were thus affected, came to the Infirmary prepared to submit to the operation. The influence of the belladonna displayed the character of the cataract, and to her great joy enabled her to read the smallest print. The centre of the capsule is seen to be irregularly opake. Its whiter colour distinguishes it from the opacity of the lens, which is much more extensive, but regular and defined. The black circle represents the transparent circumference of the lens through which light was admitted to the retina. Every morning a little of the diluted belladonna was dropped into her eye, and she saw perfectly during the

FIG. 1.

FIG. 2.

FIG. 3.

FIG. 4.

FIG. 5.

FIG. 6.

Drawn by H. Thomson.

Engraved by J. Stewart.

Published by Longman, Hurst, Rees, Orme & Brown, March 1. 1811.

rest of the day. She was content with this advantage, and declined the operation.

The other figures in this plate are intended to shew the effect of the operation on the capsule in the ordinary cataract of the adult; and, with the exception of the sixth, they are purposely taken from some of the Author's last patients. *Fig.* 2. represents the left eye of Ann Story, perfectly cured of a cataract, which consisted of a solid opake lens with an opake capsule adhering to the iris. Mr. Travers has since cured her right eye of a cataract by the same operation. By *fig.* 3. the left eye of Mary Nieve is delineated. She was affected in both eyes with lenticular cataracts, of which she was perfectly cured in this eye by three operations in the space of five months, and in the other the cure was nearly completed when the Author died. The pupil is somewhat dilated with the belladonna, to shew how considerable a portion of the anterior lamella of the capsule he thought it expe-

dient to leave *in the lenticular cataract,* for the purpose of supporting the lens in its natural situation during the process of its solution. The aperture made in the other capsule was precisely like the one which is here represented, and the Editor designedly selected the patients whose eyes are represented by *fig.* 2, 3. because, the central aperture in these being smaller than usual, they more distinctly illustrate his last operation. Nieve's was the only case in which the Author made the capsular aperture in the form which is represented by *fig.* 3. In every other instance it approached to the figure either of an oval or a circle, and he endeavoured to limit its extent to the natural size of the pupil. In the eye which *fig.* 4. represents, more of the anterior lamella of the capsule was undesignedly destroyed than he considered to be safe: barely enough was left to embrace and fix the lens. This event having happened in his third operation, he did not again operate on that eye, know-

ing that a very slight pressure of the instrument would cause the lens to revolve, and pass into the anterior chamber. He therefore left it to be slowly dissolved, for the solution of a hard lens can only be hastened by occasionally opening its texture. She had been above eight months in the Infirmary when Mr. Saunders died, at which time the appearance of the lens is represented in *fig.* 4. All that is seen posterior to the pupil, is the remains of the unabsorbed lens; its surface is irregular, and a dark spot above and below marks at each place a breach through it, by which she saw double with one eye. The solution went on very gradually, and after a few months more the pupil became perfectly clear, and she read with facility a very small print. The cure of the other eye (*fig.* 5.) had been attempted by another surgeon, but the essential point in the operation, the central aperture in the capsule, had been neglected. Under a slight dilatation of the pupil several apertures are seen in its circumference,

but its centre is blocked with the remains of an opake capsule. *Fig.* 6. is added to shew the effect of making too large an aperture in the anterior lamella of the capsule. Wheatley, admitted into the Infirmary in 1810, was dismissed with a free aperture in the capsule, and a lens partially dissolved, so as to leave a segment of the pupil clear. The eye was perfectly free from inflammation, and his vision was very useful; but as the solution went on, the large nucleus lost its support, and dropped into the anterior chamber, as it is represented. From that moment inflammation was excited, and has been kept up in different degrees for more than twelve months, by which the process of solution has not only been considerably retarded, in consequence of the effusion of coagulable lymph around this nucleus, but the cure has been rendered doubtful.

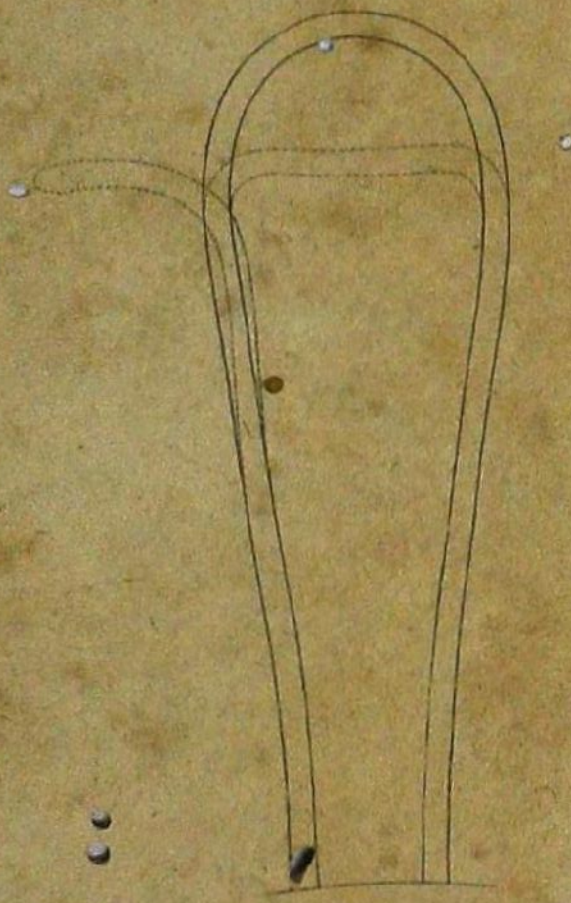

FIG. 4.

FIG. 3.

FIG. 2.

FIG. 1.



Engraved by J. Stewart, from the Instrument.

Published by Longman, Hurst, Rees, Orme & Brown, March 1, 1811.

PLATE VIII.

Fig. 1. Represents the larger needle with which the author performed his first operation of cutting up the texture of the lens and its capsule. It differs from *fig.* 2, 3. only in its size.

Fig. 2. Represents his smaller needle for the anterior and posterior operations on the capsule. Its length from the point to the extremity of the shoulder next the handle, is one inch and an eighth. From the shoulder to the centre of the blade it is round, from the centre to the point it is gradually flattened on both sides, being reduced so thin near its extremity as to be somewhat flexible, varying in this respect according to the state of the capsule. It has on both sides its point very sharp edges, which extend a little beyond its angles. Its breadth at the angles is the thirtieth part of an inch. From the point to the shoulder there is a very gradual increase in the size of the instrument. A lateral view of *fig.* 2. is given by *fig.* 3.

Fig. 4. Represents the speculum. This instrument has been varied from Pellier's in its form and in the manner of using it. Pellier applied the curved extremity upon the upper eye-lid; but as the author introduced the bow of the instrument under the upper eye-lid, the extent of the curve is diminished. Pellier's had both extremities alike, the author's has a smaller and a larger curve, which may be adapted to the eye of the child or the adult. It is convenient to have several of these instruments, differing in the size of the wire, and in the breadth of the curve. The continued lines at each end of this figure are intended for the admeasurement of the small and large ends of a middle sized speculum, and the dotted lines mark the commencement, and degree of the curve. The instruments were made by Mr. William Smith, of St. Saviour's Church Yard, who was always employed by the author for that purpose, and is the instrument-maker to the Infirmary.

FINIS.

J. M'Creery, Printer, Black-Horse-Court,
Fleet-Street, London.